

## The Value Of Distal Angiography, Selective And Subselective, In The Treatment Of Lesions Causing CLTI

Jos C. van den Berg MD PhD  
 Clinica Luganese Moncucco  
 Lugano, Switzerland



## Disclosures

- Nothing to disclose in relation to this presentation

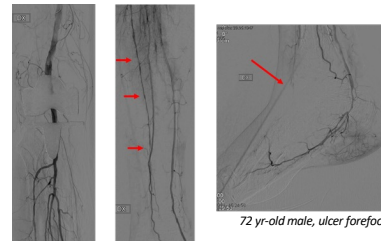


## Goal angiography

- Diagnosis and planning
- Guidance procedure
  - (super) selective angiography
    - Identification 'dormant' arteries
    - Identification small collaterals
    - Identification wound perfusion-'angiophosphomes'-wound blush (correlates with healing)



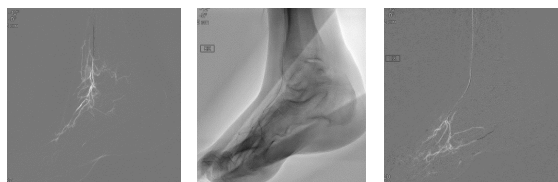## Dormant arteries



Distal angiography (non-selective)



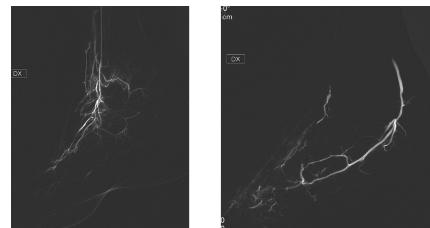
## Dormant arteries



Distal angiography (selective)

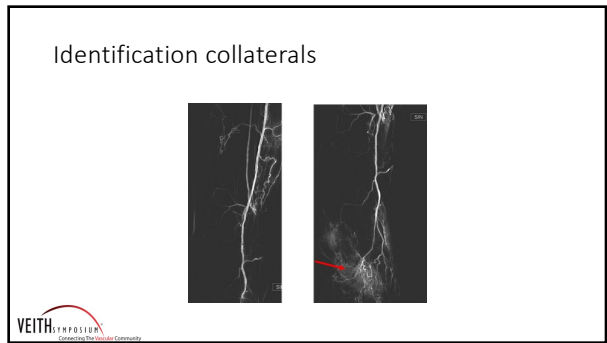
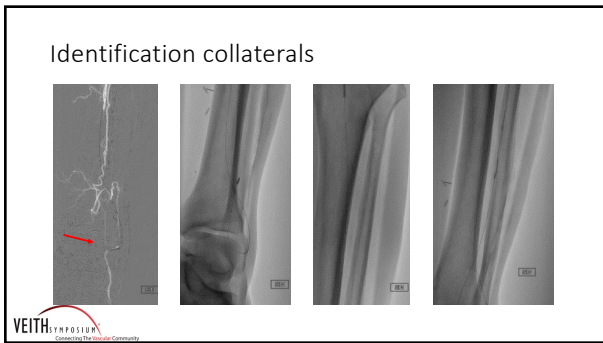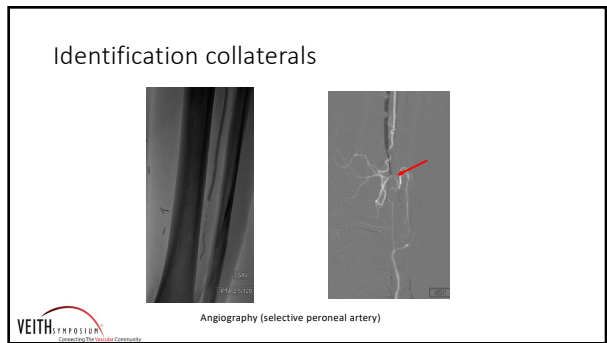
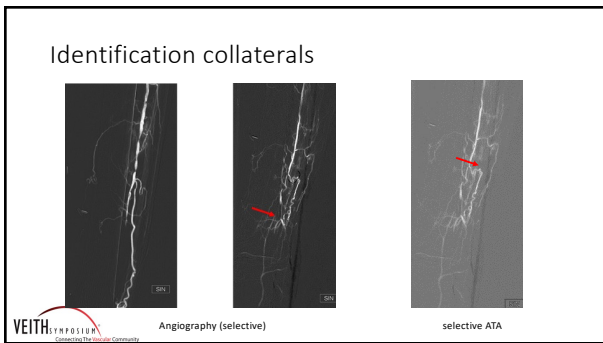
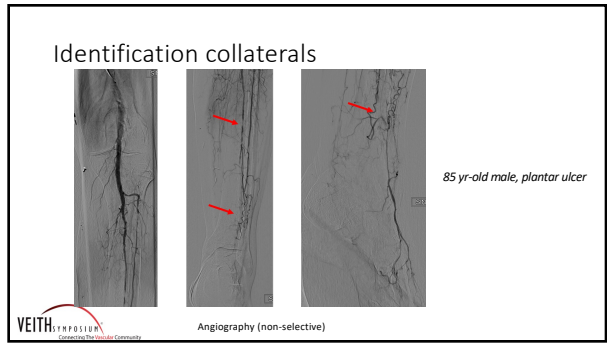

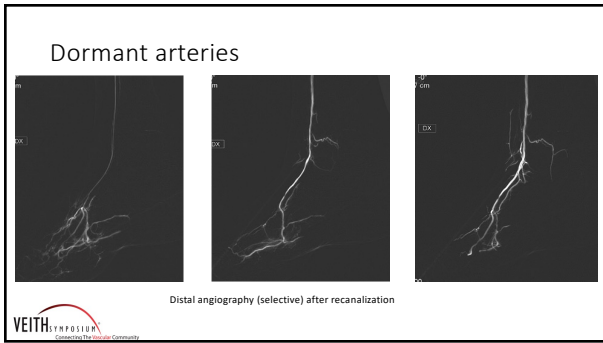
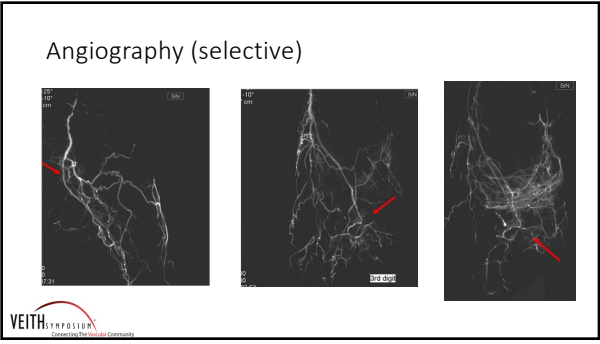

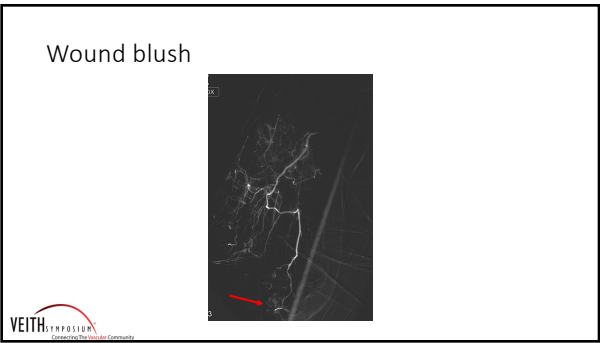
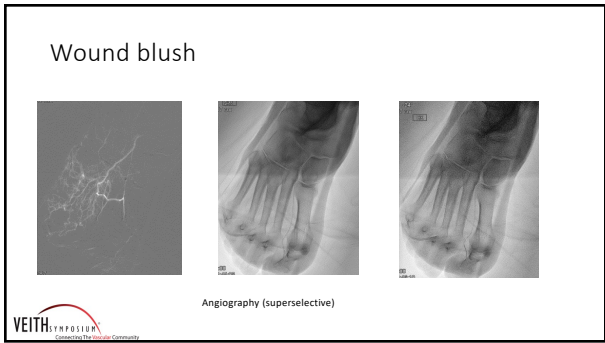
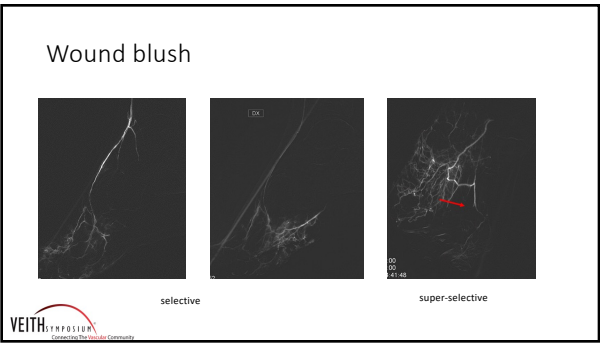
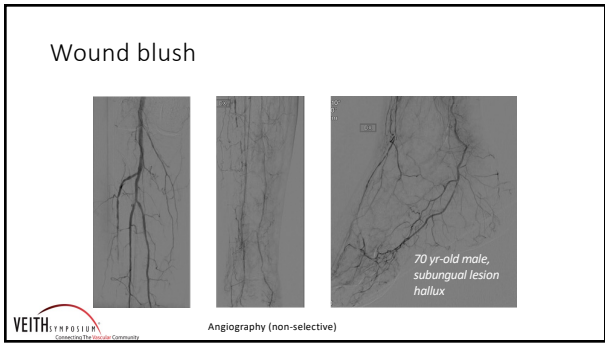
## Dormant arteries




Distal angiography (selective)









### Conclusions

- Distal selective and super-selective angiography helps in identifying 'dormant' outflow and in achieving wound directed blood flow
- Distal angiography can help in finding alternative pathways to recanalize CTO

VEITH SYMPOSIUM  
Connecting The Vascular Community

### The Value Of Distal Angiography, Selective And Subselective, In The Treatment Of Lesions Causing CLTI

Jos C. van den Berg MD PhD  
Clinica Luganese Moncucco  
Lugano, Switzerland

VEITH SYMPOSIUM  
Connecting The Vascular Community

EVD

AM