

Alternate Anatomic Approaches To Lower Extremity Arteries When Standard Approaches Are Prevented By Scarring Or Infection

Neal S Cayne, MD
 Director of Advanced Endovascular Surgery
 Co-Director Aortic Center
 New York University Langone Medical Center
 New York, NY

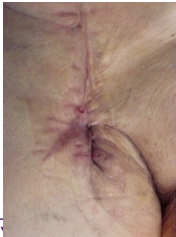

Disclosures


- Consultant – Cook, Terumo, Gore



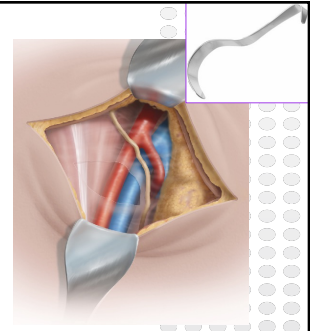
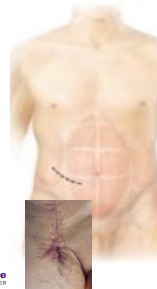Vascular Exposure Through Scarred or Infected Wounds:



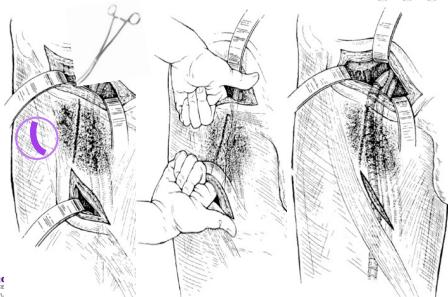
- ↑ OR time
- ↑ Risk
 - Blood Loss
 - Infection
 - Damage to vessels/nerves



External Iliac artery



Tunnel anterolateral, deep to the inguinal ligament



Obturator Canal – for infection

* Tunnel **inferomedial** to avoid obturator nerve/artery

