Transcatheter Electrosurgical Septotomy 101

Mirza Shadman Baig, MD
Clinical Associate Professor of Surgery
University of Texas Southwestern Medical Center - Dallas, TX

Division of Vascular and Endovascular Surgery

UTSouthwestern Medical Center

Disclosures

- Cook Medical, W.L. Gore, Philips
  - Clinical Investigator

- Acknowledgements
  - Loay Kabbani, MD
    Associate Professor of Surgery
    Wayne State University, Detroit, MI
  - Gustavo Oderich, MD
    Professor and Chief of Vascular Surgery
    UT Health & Memorial Hermann Texas Medical Center , Houston, TX, USA

UTSouthwestern Medical Center

Transcatheter electrosurgery

2015 → 2019

Structural heart disease: **BASILICA** and **LAMPOON** techniques

(Khan et al. JACC 2018)

Laceration of the Anterior Mitral leaflet to Prevent Outflow ObstructioN (LAMPOON)

(Kabbani L et al. JVSCI 2023)

"Powered Cheese Wire Technique" for Septal Fenestration in Complex Endovascular Repair for Chronic Thoracoabdominal Aortic Dissection

Novel technique to fenestrate an aortic dissection flap using electrocautery

Loay Kabbani, MD, Marvin Eng, MD, Kevin Onofrey, MD, Mitchell Weaver, MD, and Timothy Nygaver, MD, Detroit, MI

Transcatheter electrosurgical aortic septotomy (TEAS)

Division of Vascular and Endovascular Surgery

UTSouthwestern Medical Center

THE PRESENT AND FUTURE

JACC STATE-OF-THE-ART REVIEW

Transcatheter Electrosurgery

JACC State-of-the-Art Review

JACC;2020:75:1455-70

A B C D E

Intact guidewire insulation | Inner surface denuded | + Insulating Catheters | + Insulating Catheters + Dextrose

Department of Surgery

UTSouthwestern Medical Center

Transcatheter Electrosurgical Septotomy

ASAHI Astato® XS 20 300cm

High-tensile Stainless Steel Core

Hydrophilic Coating SLIP-COAT® | PTFE Coating

NAVICROSS® 0.018" Catheter
Minimum Sheath Compatibility: 2.6 Fr

UTSouthwestern Medical Center

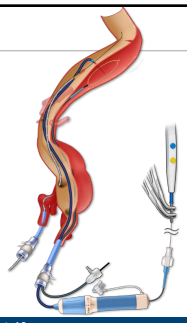

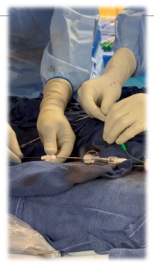

Department of Surgery

UTSouthwestern Medical Center

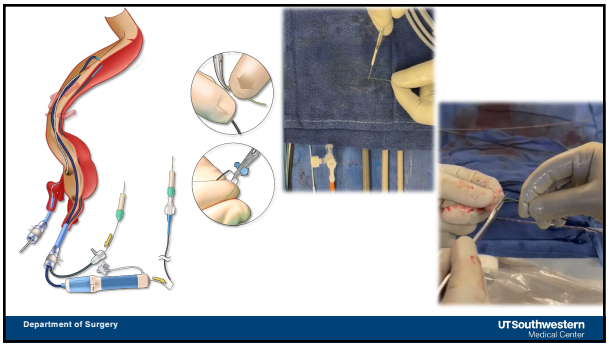
Department of Surgery
UTSouthwestern
Medical Center

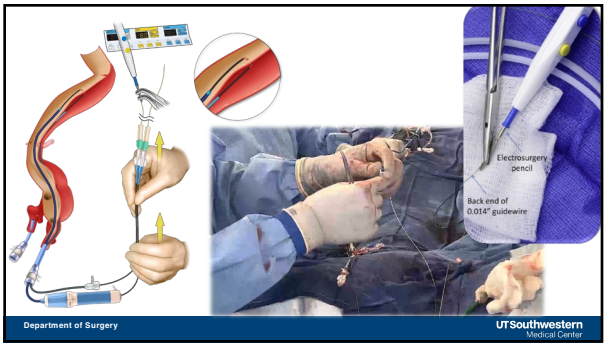
Electrosurgery pencil
Back end of 0.014" guidewire
Department of Surgery
UTSouthwestern
Medical Center

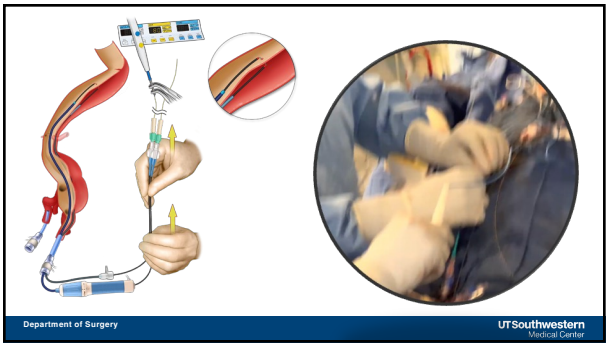
Department of Surgery
UTSouthwestern
Medical Center

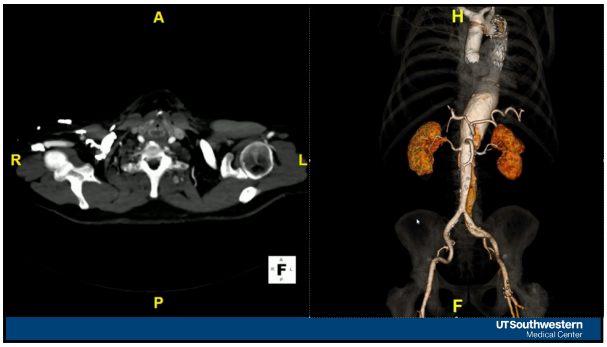
A
R
L
P
F
H
F
UTSouthwestern
Medical Center

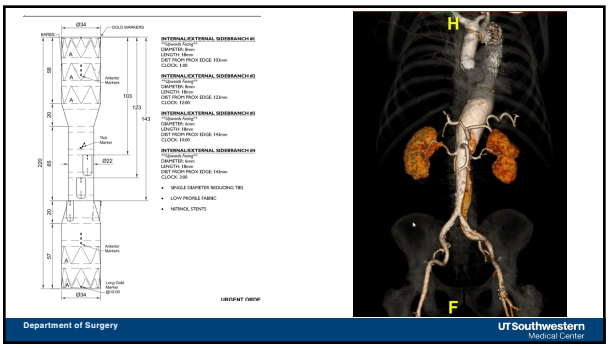
Department of Surgery
UTSouthwestern
Medical Center

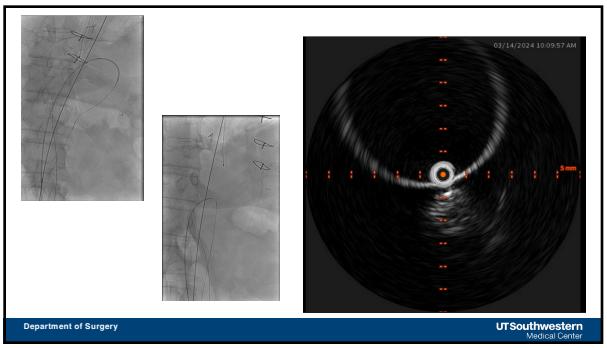
03/14/2024 10:09:57 AM
5 mm
Department of Surgery
UTSouthwestern
Medical Center

Septotomy

Post-IVUS

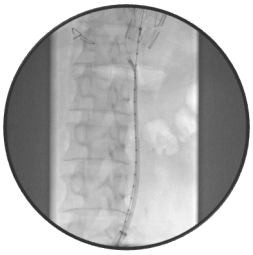

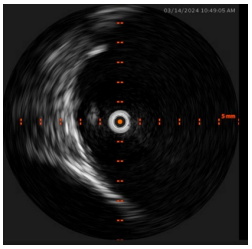

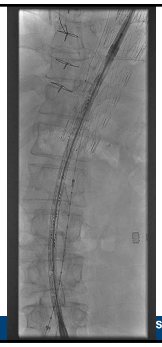

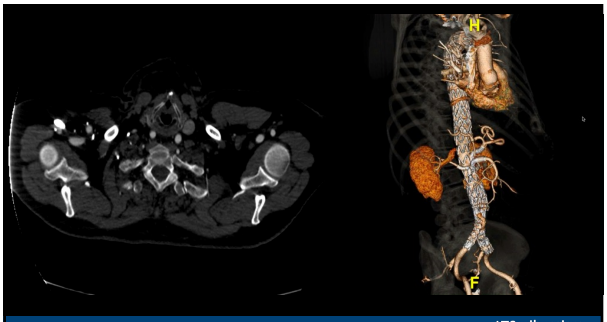

Conclusion

- TEAS can be performed safely and reliably.
- TEAS facilitates endovascular repair, particularly in narrow true lumen and when target vessels arise from false lumen
- Full fluoroscopic visualization is needed to avoid injury
- Mural thrombus or thick septum should be avoided
- Longer follow up is needed to assess durability and frequency of endoleaks after FBEVAR for PD-TAAAs