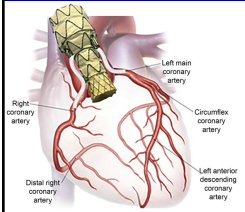
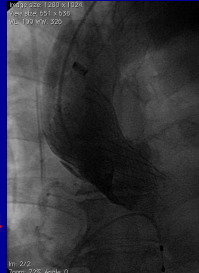

**Advances In Endograft Repair Of The Ascending Aorta Without And With Involvement Of The Aortic Valve (Endo-Bentall): What Lesions Are Or Will Be Suitable: World Clinical Experience With Endo-Bentall To Date**

Ali Khojnejhad MD, PhD, FACS  
 Director of Aortic & Arrhythmia Surgery  
 MemorialCare Heart & Vascular Institute  
 Los Angeles, CA



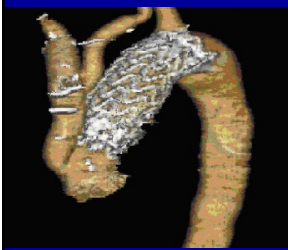
**Veith 2024**



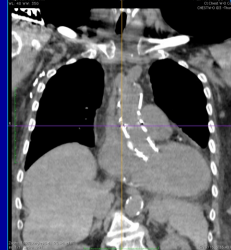
**No financial interest!**

**My disclosure: optimist!**

Many aortic pathologies amenable to Endo-Bentall?  
 Not currently! But most probably soon!




Yours Sincerely – Omaha 2007



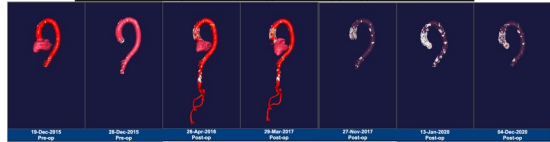
Yours Sincerely – Los Angeles 2014

**First Physician-Sponsored IDE in the Ascending Aortic Pathologies**  
 National Co-PIs: White/Khojnejhad



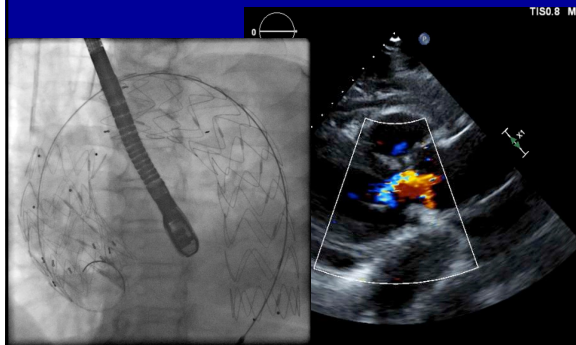
**Five year f/u of TEVAR type A dissection**

5 Year Follow Up – Ascending TEVAR s/p Type A Dissection

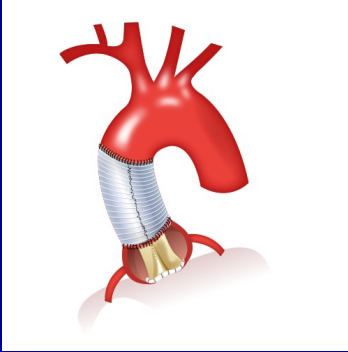


Khojnejhad A, et al. Ann Cardiovasc Surg 2021.

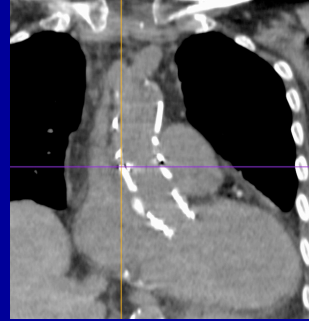
**PS-IDE Ascending TEVAR with moderate AI**



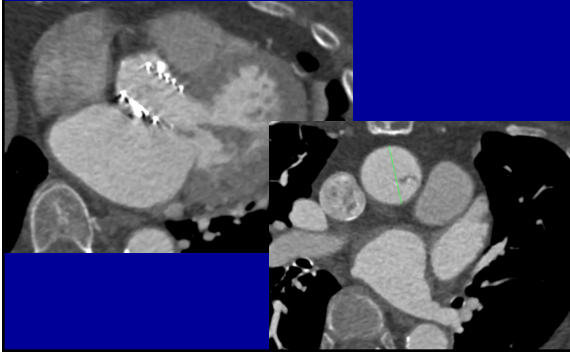
## Lingo: Wheat operation



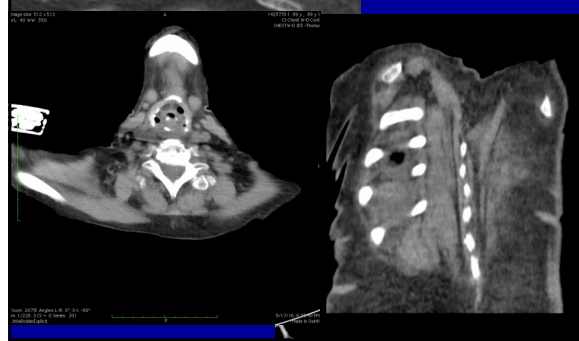
## Example: Endo-Wheat



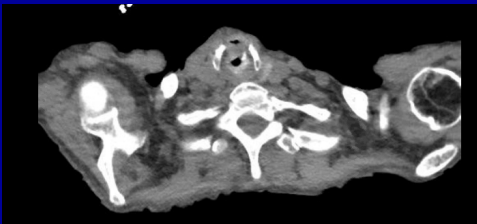## 89 yo with post TAVR aortic dissection



## Endo-Wheat: early results



## Endo-Wheat: seven-year f/u



## Anatomic feasibility of an endovascular valve-carrying conduit for the treatment of type A aortic dissection

Maximilian Kreibich, MD,<sup>a,b</sup> Tobias Sockeland, MS,<sup>a,b</sup> Friedhelm Beyersdorf, MD,<sup>a,b</sup> Joseph E. Bavaria, MD,<sup>c</sup> Holger Schröfel, MD,<sup>a,b</sup> Martin Czerny, MD, MBA,<sup>a,b</sup> and Bartosz Rylski, MD<sup>a,b</sup>

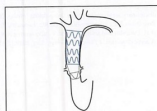
### ABSTRACT

**Objective:** The study objective was to screen patients with acute type A aortic dissection for anatomic feasibility of ascending aortic endovascular treatment with a valve-carrying conduit.

**Methods:** High-quality computed tomography scans of 167 patients were available for screening. Aortic dimensions were measured using multiplanar reconstruction in the plane perpendicular to the manually corrected aortic center line. The simulated stent-graft 10-mm-long landing zones were measured starting at the sinotubular junction (proximal landing zone) and ending at the brachiocephalic trunk (distal landing zone). Exclusion criterion was an entry within the aortic root or the landing zone.

**Results:** In 113 patients (68%), the entry was in a coverable zone in the ascending aorta with sufficient proximal and distal landing zone or in more distal aortic segments. In these patients, the median distance between the proximal and distal landing zone was 89.1 (first quartile: 80.0 mm; third quartile: 101.2 mm) and the median diameter difference was 5.0 mm (2.0; 10.1) (12.3 [4.9; 23.0] %). The diameter difference was less than 2 mm in 32 patients (28%), between 6 mm and 10 mm in 20 patients (18%), between 10 mm and 14 mm in 11 patients (10%), and 14 mm or greater in 10 patients (9%).

**Conclusions:** Two thirds of all patients who present with type A dissections are potential candidates for treatment with endovascular valve-carrying conduits, but most patients would require tapered stent-grafts. (*J Thorac Cardiovasc Surg* 2019;157:26-34)

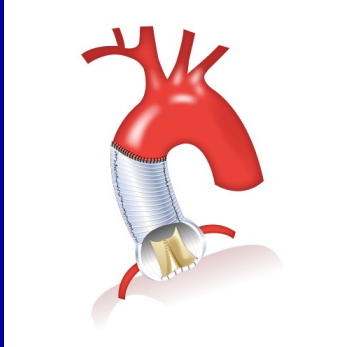


Treating a type A dissection with an endovascular valve-carrying conduit.

**Central Message**  
An endovascular valve-carrying conduit may be a new treatment option for many patients with a type A aortic dissection.

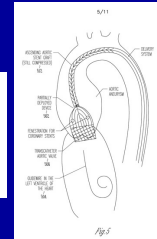
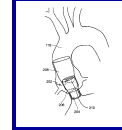
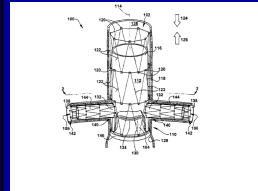
**Perspective**  
High-quality CT scans of 167 patients with type A aortic dissection were screened for the anatomic feasibility of ascending aortic endovascular treatment with a valve-carrying conduit. Two thirds of those patients are potential candidates for the treatment, but most patients would require tapered stent-grafts.

## Terminology: Bentall operation



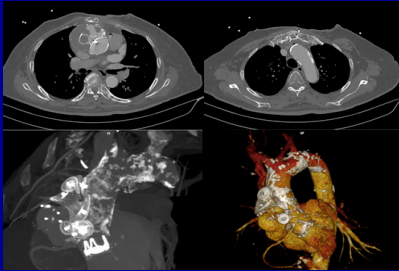
## Endo-Bentall

- need reliable TAVR and ascending TEVAR stent
- multiple IPs, first in-human
- IDE devices within next 5 years



## First in-human Endo-Bentall

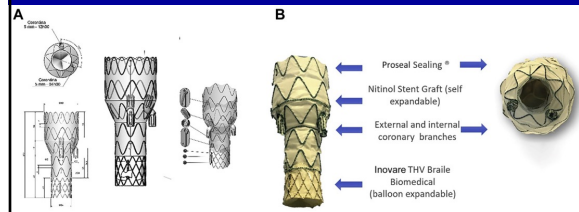
- failing Perimount AVR & aortic pseudo-aneurysm



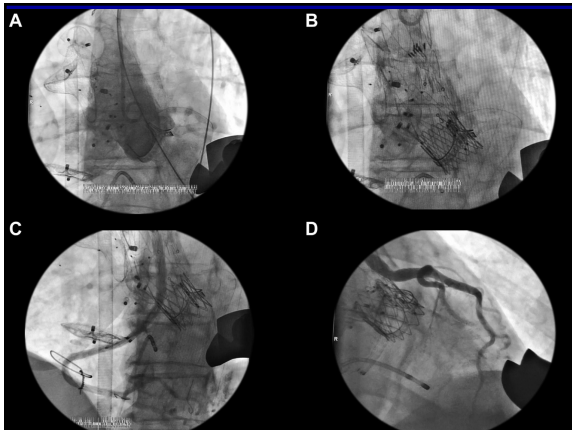
Diego Felipe Gaia et al. *J Am Coll Cardiol Case Rep* 2020; 2:480-485.

## First in-human Endo-Bentall

- Device selection

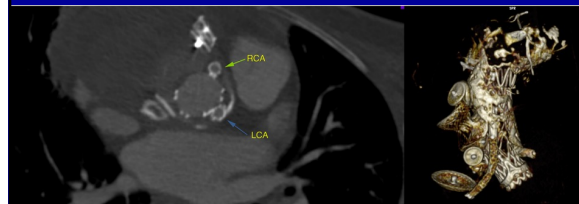


Diego Felipe Gaia et al. *J Am Coll Cardiol Case Rep* 2020; 2:480-485.



## First in-human Endo-Bentall

- 4-month follow-up



Diego Felipe Gaia et al. *J Am Coll Cardiol Case Rep* 2020; 2:480-485.

## The (near) *Future* of the Aortic Root Operations

- 1) Bentall/David hemiarch
- 2) Bentall/David accommodating zone 0 TEVAR
- 3) Endo-Bentall
- 4) Endo-Bentall accommodating zone 0 TEVAR



## Conclusions

- ◆ Endovascular treatment for the ascending aorta is here!
- ◆ Multiple companies and our PS-IDE with acceptable or promising early results
- ◆ Endo-Wheat is suited for high-risk type A dissections!
- ◆ 2/3 of type A dissections are candidates for Endo-Wheat
- ◆ Endo-Bentall: Many technical challenges
- ◆ First successful in-human Endo-Bentall with physician modified devices and a few other reports

