


Are Lymphedema, Lipedema, And Edema Related?

Steven M. Dean, DO, MSVM, RPVI
Clinical Professor of Medicine
Division of Cardiovascular Medicine
The Ohio State University Wexner Medical Center

DISCLOSURE

Tactile Medical:
Speaker's Bureau
Scientific Advisory Board



Are Lymphedema, Lipedema, And Edema Related?

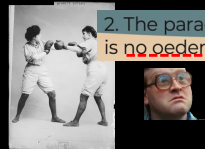


Standard of care for lipedema in the United States

JWCI International Consensus Document

"...no lipedema-induced lymphedema, but rather **obesity-associated lymphedema**"

2. The paradigm shift: there is **no oedema** in lipoedema



Reference: 2021;doi:10.7797/2479-706-2021-11015807. Cpub: 2021 May 21

JOURNAL OF VASCULAR CARE - consensus document on the diagnosis and treatment of

Causes of Edema in Lipedema Patients:


Documento de Consenso
LIPEDEMA
2018

- Orthostatic edema**
Most common type of edema, that worsens through the day and improves with decubitis
- Edema associated with venous insufficiency** This group does not consider the term phlebolymphe'dema suitable despite existing in analyzed literature, as it contributes to the confusion already present. Chronic venous disorders that can be associated with lipedema, should be denominated according to the classification CEAP
- Edema due to lymphatic insufficiency; there is controversy** about this edema whether it is lymphedema associated with lipedema, constituting the so called lipolymphe'dema or if it's a secondary lymphedema due to obesity. Given that this is not always present in patients with a high BMI, we consider that they can be present in both situations.

© 2018 ALICIA M. ALONSO ALVAREZ, ANTONIOLA A. DOMINGO F. GARCIA GARCIA A. ORFILA GARCIA M. JESUS VARGAS L. INSA NPOLE. MARTIN CASTELLON. MARTINEZ ALVAREZ JR. DIVA RODRIGUEZ M. RODRIGUEZ A. YOLANDA MARTIN AL.

Orthostatic Edema

Dysfunctional Venoarterial Reflex or "Postural Vasoconstriction Reflex" with a failure to increase the precapillary resistance when the limb is dependent



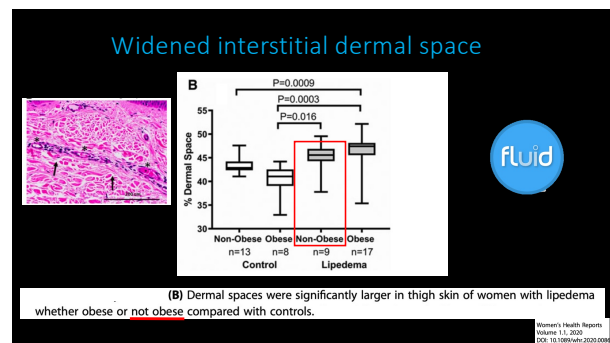
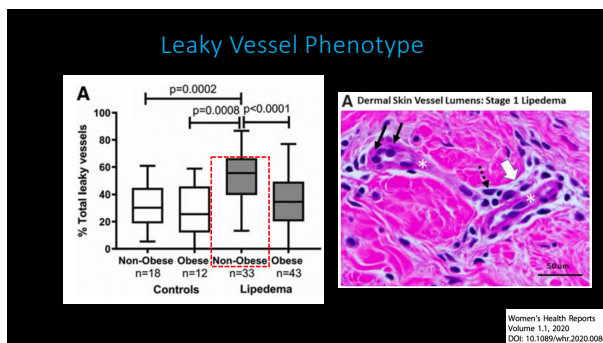
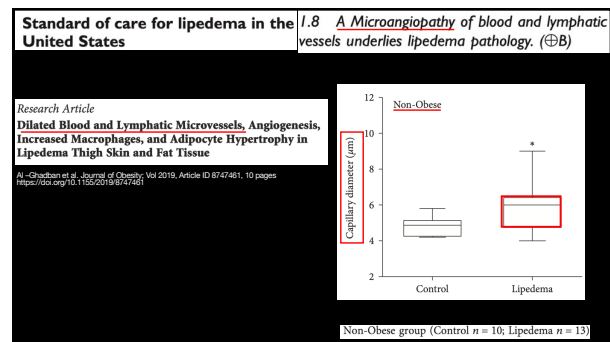
JWCI International Consensus Document

2. The paradigm shift: there is no oedema in lipoedema

“It should be clarified that patients diagnosed with lipoedema *can certainly present with orthostatic oedema, ...*”


JOURNAL OF WOUND CARE | CONSENSUS DOCUMENT VOL.29, SUP. 2, NO.11, NOVEMBER 2020

Lipoedema with Secondary Lymphedema “Lipo-Lymphedema”



Lipedema: *Lymphoscintigraphy*

- **Forner-Cordero 2018:** 83 patients with lipedema- **47%** displayed abnormal imaging.
- The degree of lymphoscintigraphic involvement bore *no relation* to the BMI (P=.832).



Rev Esp Med Nucl Imagin Med
New Dis. 2018;37(3):341-348.


Lymphatic function and anatomy in **early** stages of lipedema

John C. Rasmussen¹, Melissa B. Aldrich¹, Caroline E. Fife², Karen L. Herbst³ and Eva M. Seivick-Muraca¹

- **Methods:** 20 Stage I and II lipedema subjects, who had *not* progressed to lipolymphedema evaluated via NIRF-LI (compared to controls)
- Mean age: 38; mean BMI: **29**
- Dilated lymphatic vessels were observed in **98%** of all legs regardless of stage.
- Conclusion: Lipedema patients *without* lipolymphedema have **abnormal lymphatic anatomy** compared to controls

Rasmussen et al. Obesity (Silver Spring). 2022 Jul;30(7):1391-1400

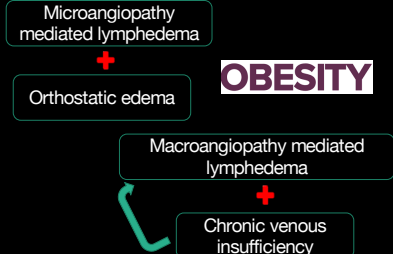
Lipedema with CVI and 2^o Lymphedema



Dean SM et al. J Vasc Surg: Ven Lymph Dis 2020.

Are Lymphedema, Lipedema, And Edema Related? Irrespective of Obesity!

YES!



The diagram shows a flow of relationships: Microangiopathy mediated lymphedema leads to Orthostatic edema. OBESITY is shown as a central factor. Macroangiopathy mediated lymphedema leads to Chronic venous insufficiency. A green arrow points from Chronic venous insufficiency back to Orthostatic edema. A green circle with 'YES!' is in the top right corner.

THE END