
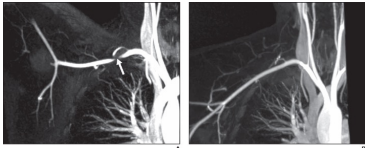


Supraclavicular Approach to Arterial And Neurogenic Thoracic Outlet Syndromes

Mark A Adelman, MD
Frank J Veith Endowed Professor of Surgery (Ret.)
NYU Medical Center

Ramesh K Tripathi MD, FRCS, FRACS Vasc., DFSVS






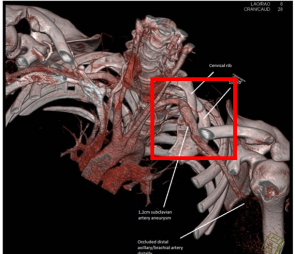
Disclosures

- None





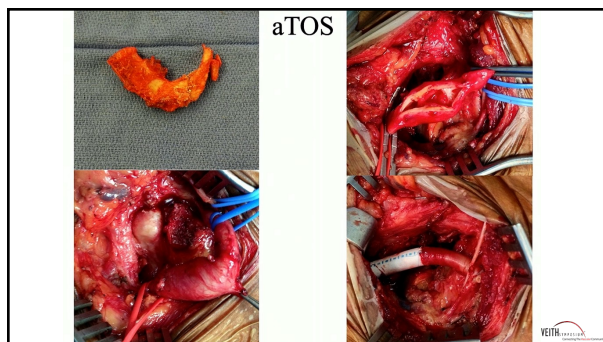
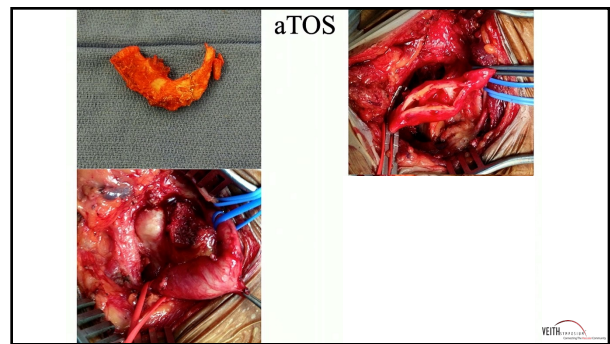
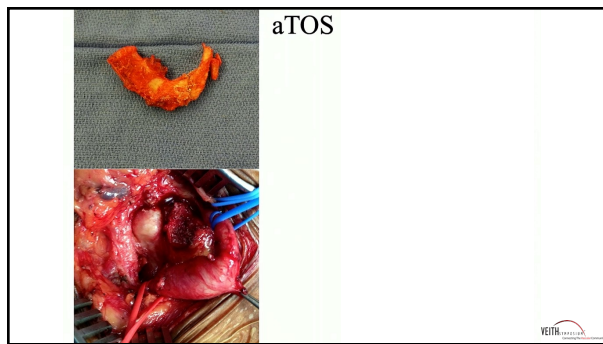
Anatomy--Constricting Elements

- Scalenii Anticus/Medius
- 1st Rib
- Cervical Rib
- Prominent T7 Process
- Clavicular/1st Fracture Callus




aTOS





Tips and Tricks

- Know ALL of the Regional Anatomy
 - (Nerves, Arteries, Veins, Thoracic Duct)
- Bipolar Cautery may be useful
- Avoid
 - Posterior exposure, Scalenus Medius—Long Thoracic Nerve
 - Medial Exposure—Subclavian/Innominate Veins, Phrenic Nerve



The chest X-ray shows the thoracic cavity with the lungs and heart. It is used to illustrate the anatomical structures mentioned in the tips and tricks.

Supraclavicular Approach to Arterial And Neurogenic Thoracic Outlet Syndromes

Mark A Adelman, MD
Frank J Veith Endowed Professor of Surgery (Ret.)
NYU Medical Center

Ramesh K Tripathi MD, FRCS, FRACS Vasc., DFSVS

The two angiographic images show the supraclavicular region, highlighting the arterial and venous structures. The left image shows the arterial system, and the right image shows the venous system.