

**MAYO CLINIC**

### THE REAL TRUTH ABOUT USE OF CRYOPRESERVED CONDUITS TO TREAT INFECTED AORTIC/ ARTERIAL RECONSTRUCTIONS

THERE ARE ADVANTAGES AND LIMITATIONS

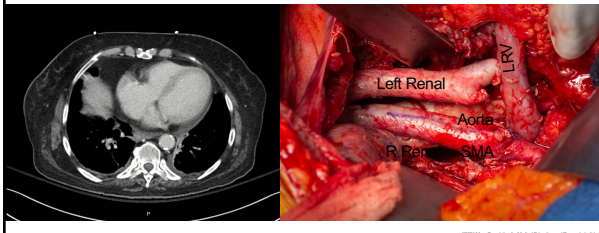
Randall DeMartino, MD, MS  
Manju Kalra, MS

VEITH Symposium  
November 22, 2024

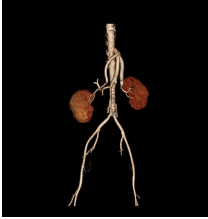
### DISCLOSURES

- No Financial Disclosures


### 67 YO FEMALE WITH BACKPAIN MSSA MYCOTIC ANEURYSM



### INITIAL POST OP SCAN AFTER SMA, RENAL AND AORTIC RECONSTRUCTION

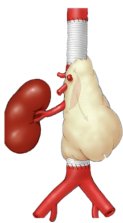


### 18 MO AFTER DISCHARGE WITH RECURRENT INFECTION AND PSEUDOANEURYSMS



### VASCULAR INFECTION

- Infected aortic grafts & aneurysms are associated with high in-hospital mortality
- Shift from extra-anatomic reconstruction to in-situ repair (ISR) when feasible

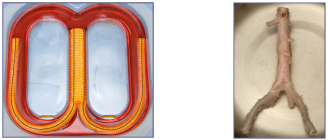


**MAYO CLINIC**

### OPTIMAL CONDUIT

**MAYO CLINIC**

- Cryopreserved aortic allograft (CAA) and Rifampin soaked Dacron (RSD) are conduit options
- No consensus on optimal conduit choice




### WHAT IS OUR UNDERSTANDING OF CRYOGRAFTS

**MAYO CLINIC**

How do they compare regarding...

- Long-term survival
- Graft-related reintervention
- Reinfection

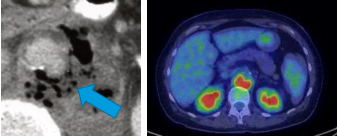
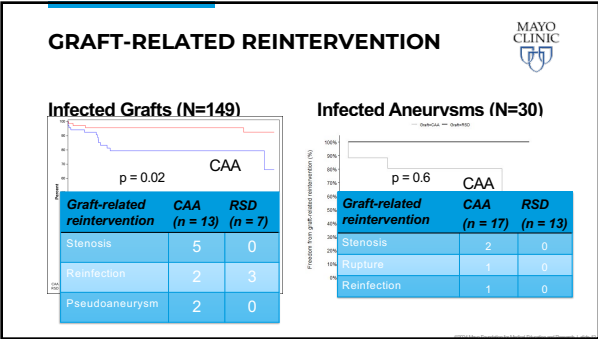
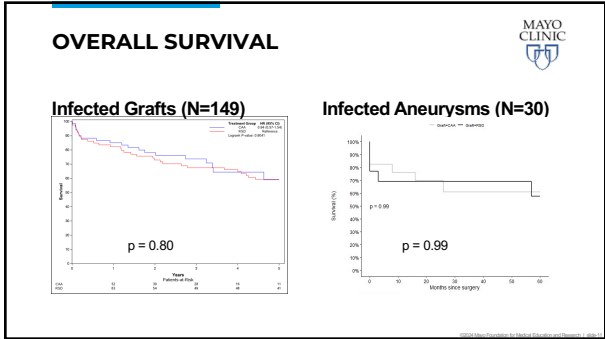
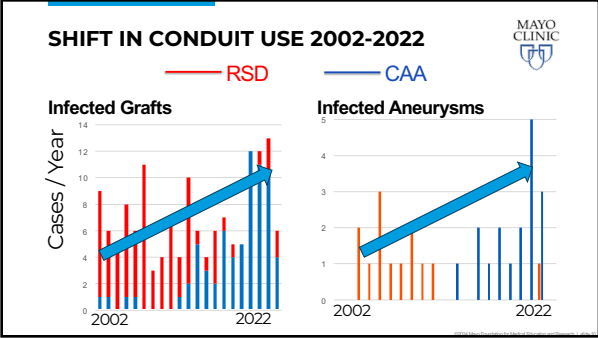


### INFECTED GRAFT & ANEURYSM EXPERIENCE AT MAYO CLINIC 2002-2020

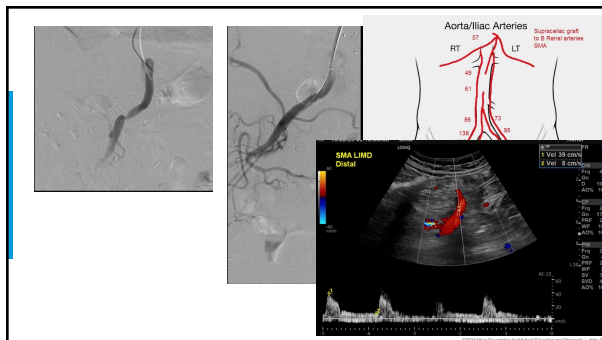
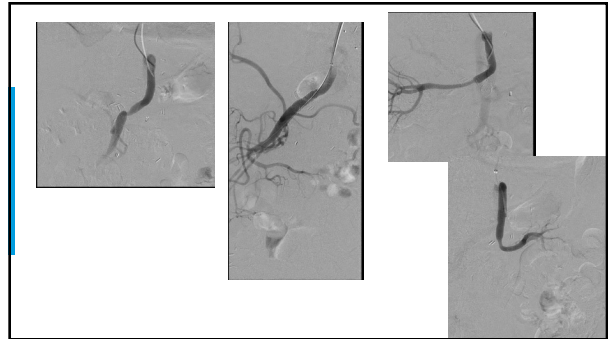
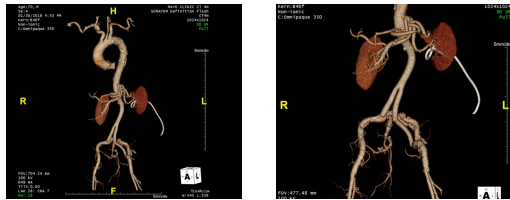
**MAYO CLINIC**

Infections diagnosed by:

- Typical imaging evidence
- Intraoperative findings
- Clinical presentation

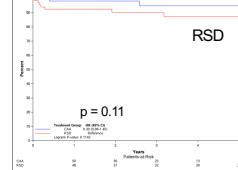



**69YO WITH *M. BOVIS* GRAFT INFECTION AFTER CRYO SMA, RENAL AND AORTIC RECONSTRUCTION**

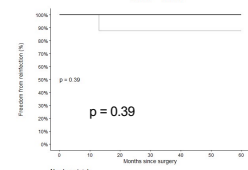


**REINFECTION**

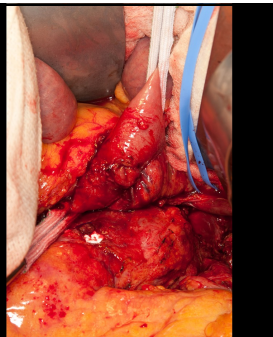
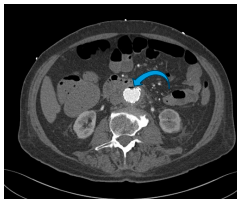
**Infected Grafts (N=149)**



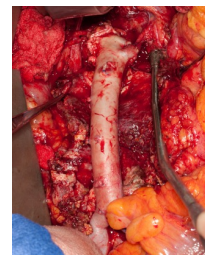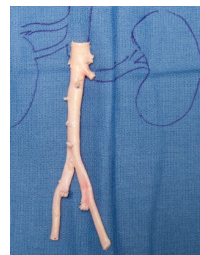
**Infected Aneurysms (N=30)**



**72 YO WITH INFECTED EVAR FROM DUODENAL EROSION**




**72 YO WITH INFECTED EVAR FROM DUODENAL EROSION**




### 10 YEARS POST OP IMAGING

- Key points
  - Fascia lata buttressing
  - Full 360° omental wrap




### MAYO CLINIC PRACTICE



- Older patients
- Highly virulent microorganisms
- Intraabdominal abscesses

} CAA

### MAYO CLINIC PRACTICE



- Older patients
- Highly virulent microorganisms
- Intraabdominal abscesses

} CAA


- Younger patients
- Urgent cases

} RSD

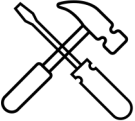
### CRYOPRESERVED ALLOGRAFTS

<p><b>Advantages</b></p> <ul style="list-style-type: none"> <li>• Readily available</li> <li>• Can get off antibiotics</li> <li>• Useful in highly infected fields</li> <li>• Reinfection rare</li> </ul>	<p><b>Limitaitons</b></p> <ul style="list-style-type: none"> <li>• \$\$\$</li> <li>• Aneurysm degeneration</li> <li>• Stenosis of visceral/iliac anastomoses</li> </ul>
---	---

### CONCLUSIONS



- Comparable early and long-term morbidity and mortality between CAA and RSD
- Both remain viable options for in-situ reconstruction and need to be customized for each patients' characteristics



### THANK YOU

