

VEITHsymposium™ 2024  
November 22, 2024

**Why Open Repair  
Is The Best Treatment  
For Mycotic AAAs:  
Is EVAR Ever Of Value**

**Y Tshomba**  
Vascular Surgery Chief & Program Director  
at The Department of Cardiovascular & Thoracic Sciences



Fondazione Policlinico Universitario A. Gemelli  
Università Cattolica del Sacro Cuore

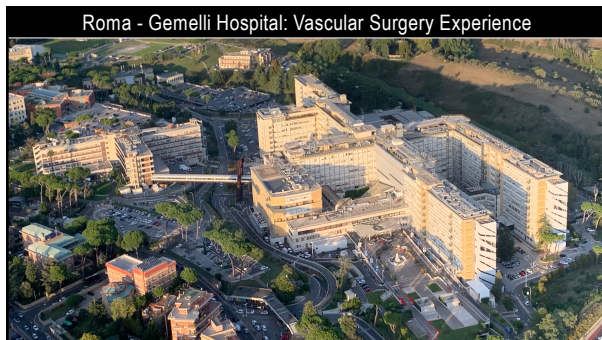**Nuovo Gemelli Cuore**

**Gemelli**  
Fondazione Policlinico Universitario A. Gemelli  
Università Cattolica del Sacro Cuore

**Disclosures**

I have no actual or potential conflicts  
of interest in relation to this presentation

Università Cattolica del Sacro Cuore - Scientific Institute Policlinico A. Gemelli, Roma - Italy



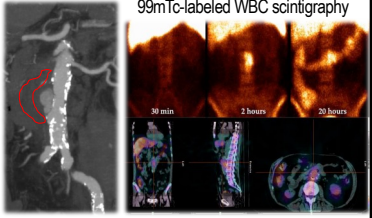
**Gemelli**  
Fondazione Policlinico Universitario A. Gemelli  
Università Cattolica del Sacro Cuore

**Our experience 2010-2024**

**37 mycotic AAAs**

- Contained rupture 27 (70%)
  - Intact 7 (17%)
- Free rupture/shock 3 (7%)

• Staphylococcus Aureus 27%  
• Escherichia Coli 13%  
• 13 pts + >1 pathogen



99mTc-labeled WBC scintigraphy  
30 min 2 hours 30 hours

Università Cattolica del Sacro Cuore - Scientific Institute Policlinico A. Gemelli, Roma - Italy

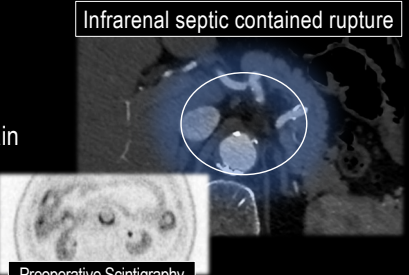
Clinical cases

**Case #1**


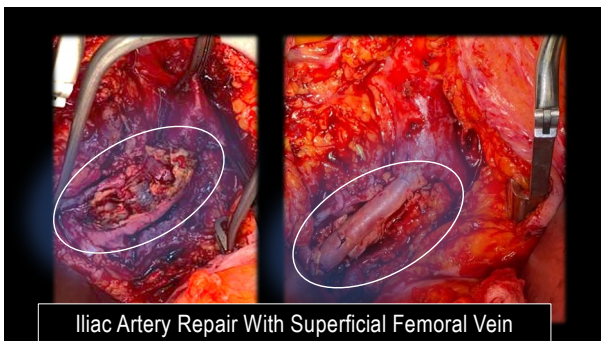
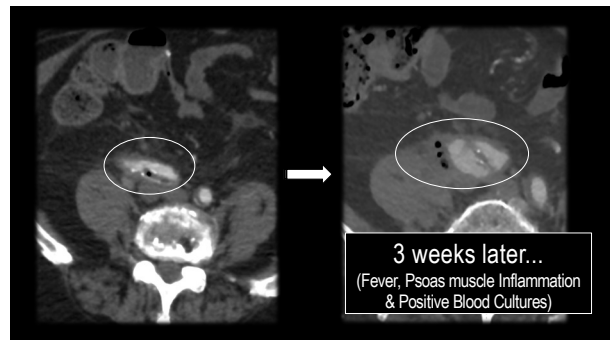
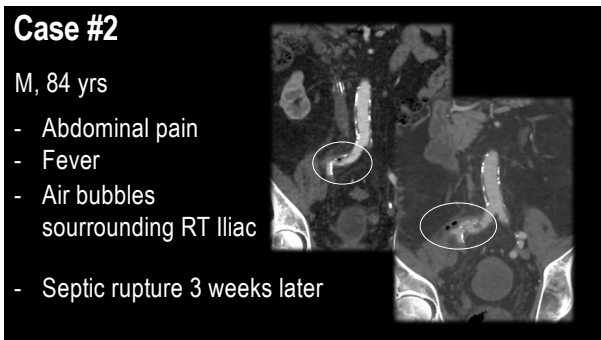
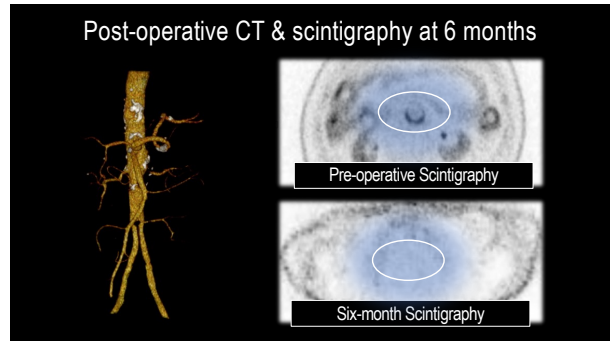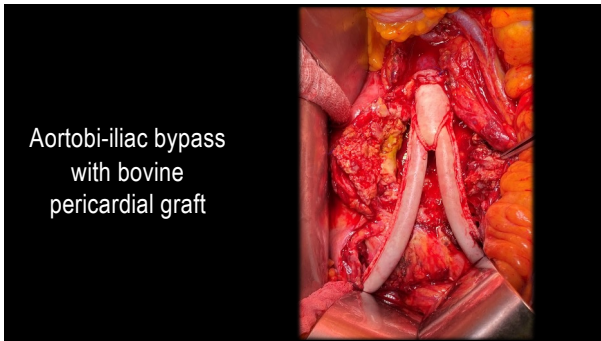
Infrarenal septic contained rupture

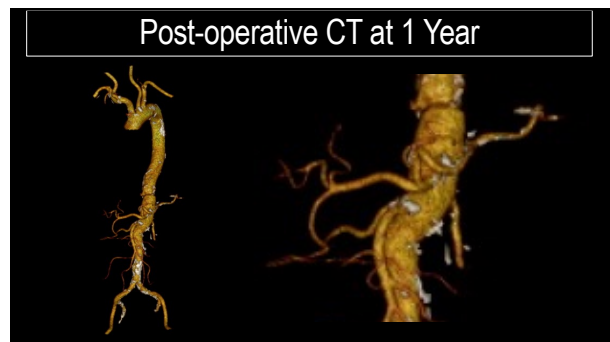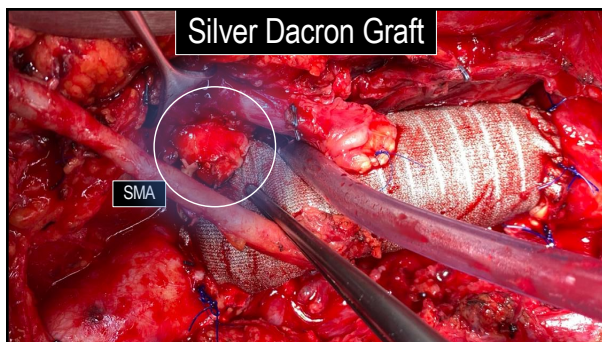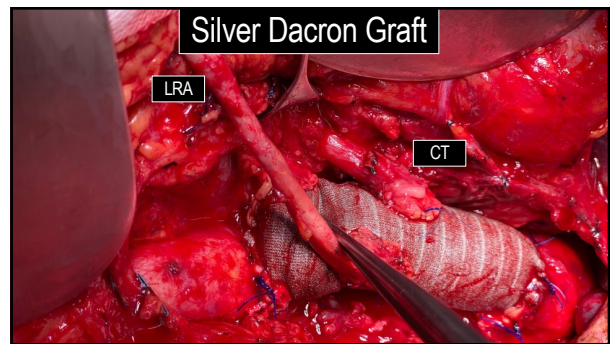
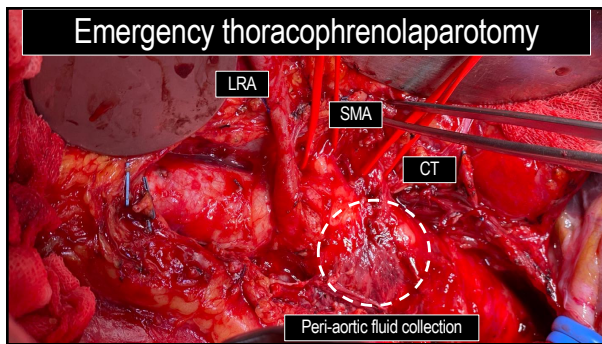
M, 78 yrs

- Abdominal pain
- High fever
- Asthenia

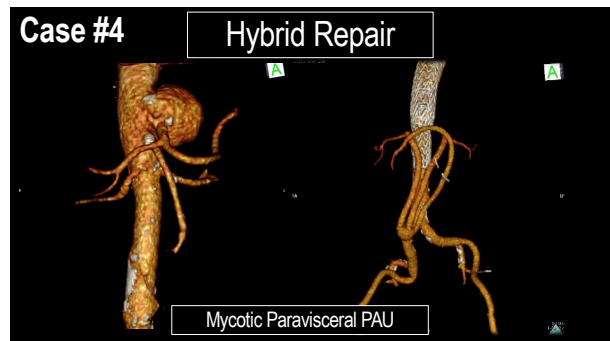


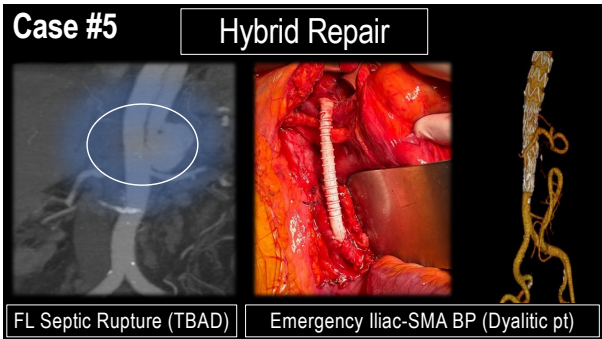
Preoperative Scintigraphy



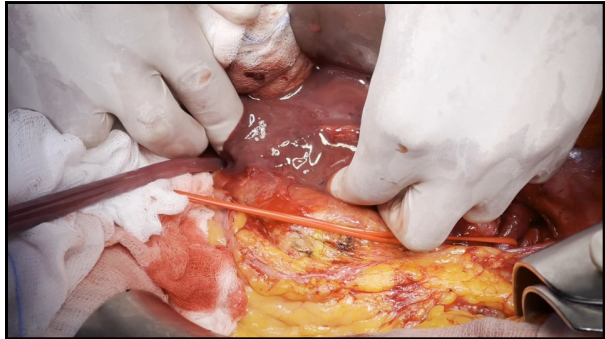
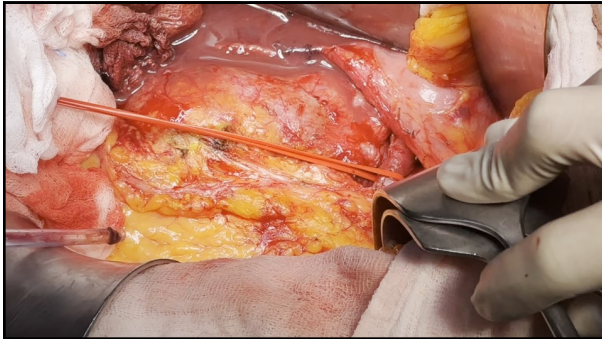
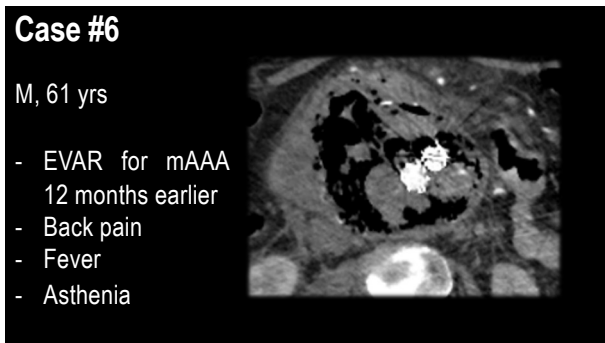
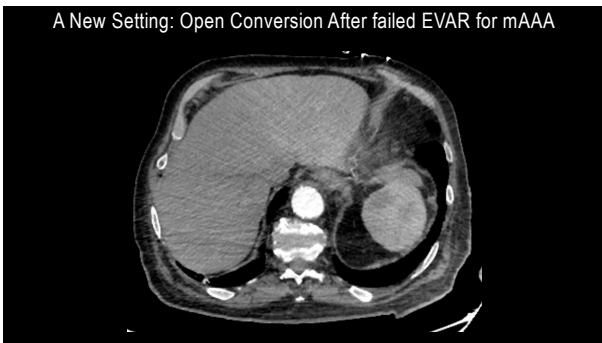


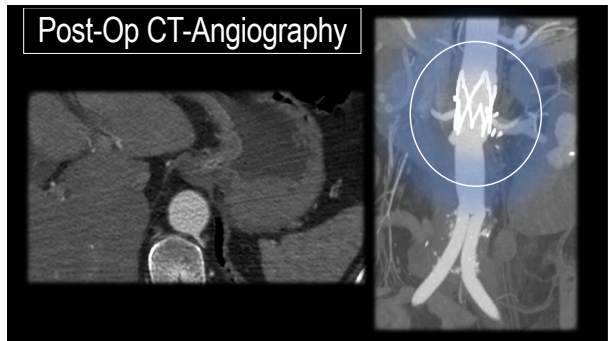
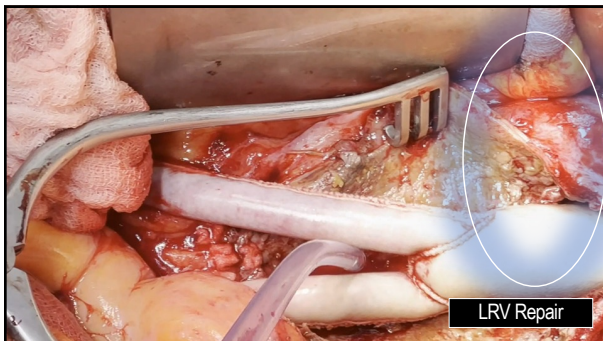
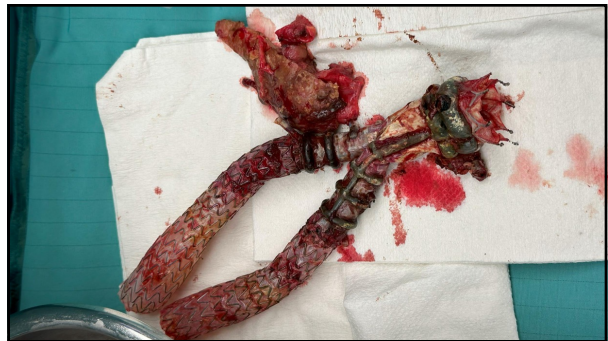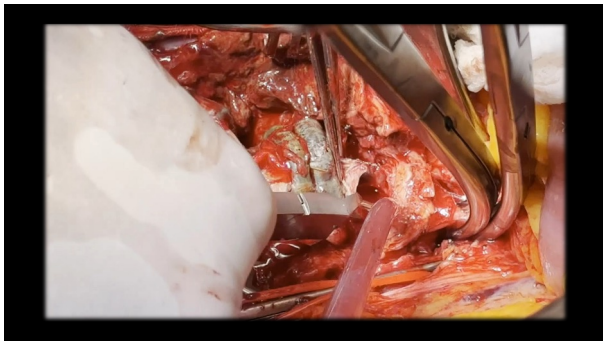
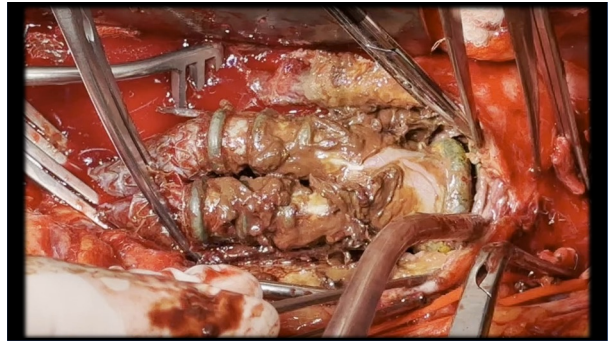
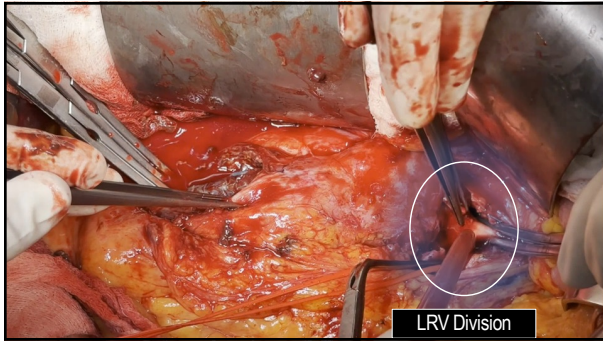
Paravisceral septic ruptures  
in pts unfit for thoracotomy?





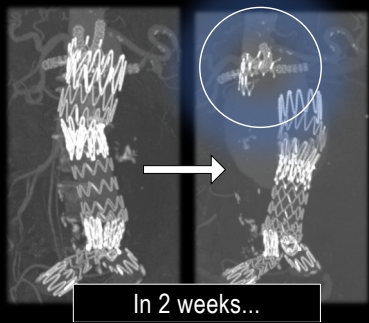
Long-term results after endograft deployment?





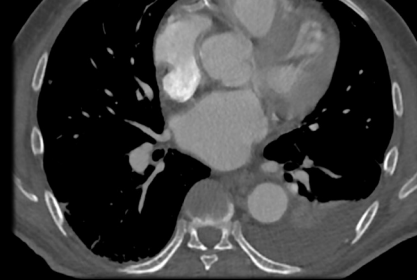**Case #7**

EVAR + proximal cuff and double chimney of renal arteries for mycotic aneurysm (Other Center)

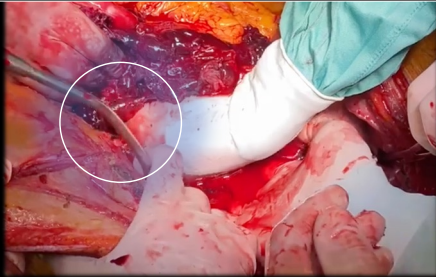


In 2 weeks...

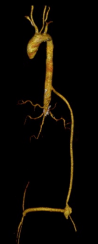
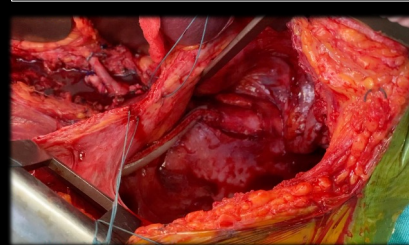
**Haemorrhagic Shock**



**Emergency Thoracophrenolaparotomy**



**Juxtarenal Aortic Ligature**



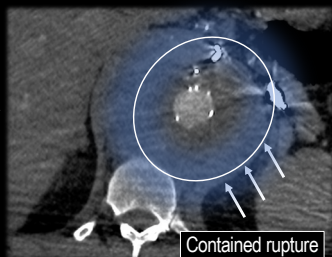
Thoraco-bi-femoral Bypass With Bovine Pericardial Graft

1-Year CTA

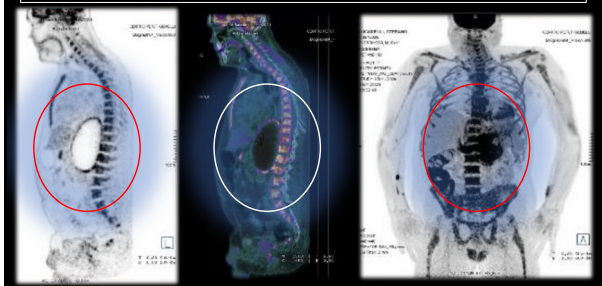
**Case #8**

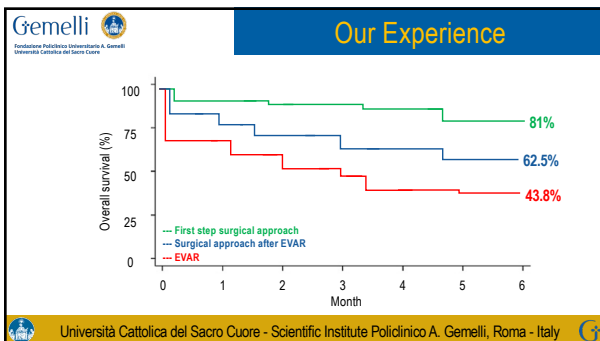
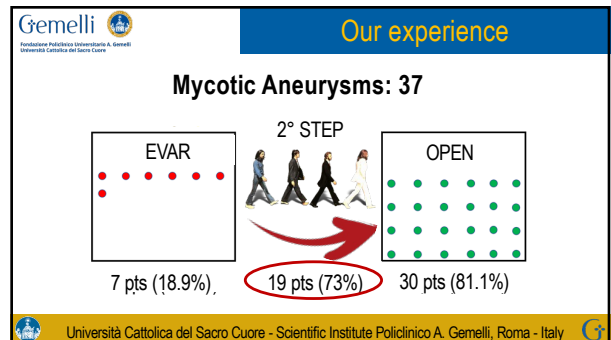
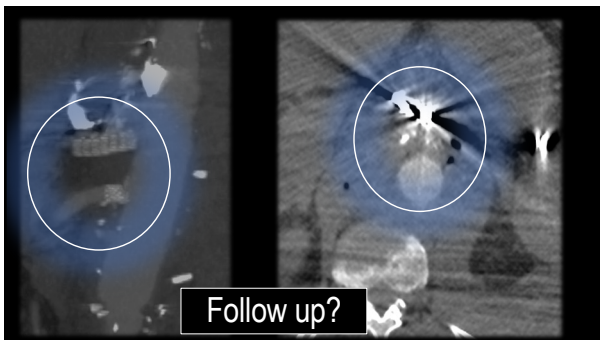
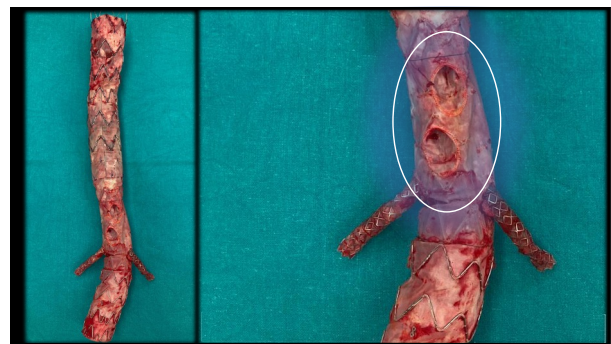
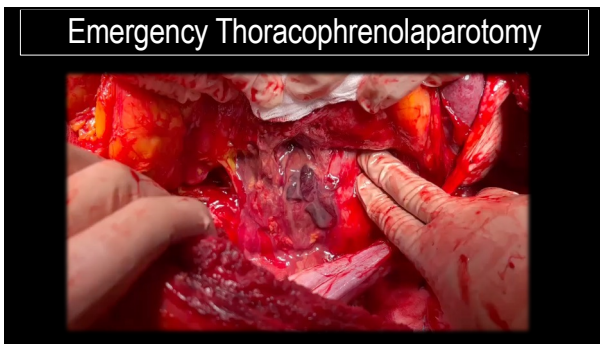M, 68 yrs

- EnSide for mTAAA 6 months earlier
- Back pain
- Rapid TAAA growth
- Fever > 40 °C



**TAAA Tracer Captation**





### Conclusion

#### EVAR for Mycotic Aneurysm

- Effective stop gap procedure in emergency
  - Careful Follow Up

Università Cattolica del Sacro Cuore - Scientific Institute Policlinico A. Gemelli, Roma - Italy

**Gemelli**  
Fondazione Policlinica Universitaria A. Gemelli  
Università Cattolica del Sacro Cuore

**Conclusion**

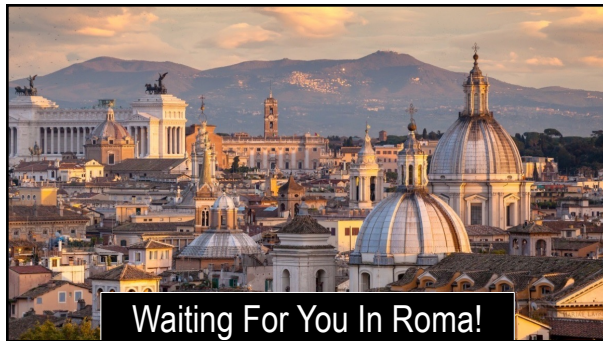## Open for Mycotic Aneurysm (Fit Pts)

- Best long term results
- Radical tissues debridement
- Better diagnosis (direct aortic cultures)
- Biological / dedicated graft

Università Cattolica del Sacro Cuore - Scientific Institute Policlinico A. Gemelli, Roma - Italy

**Thank You!**

**Aortic Team** **CHIRURGIA VASCOLARE** **Vascular Team**



**UCBM**  
UNIVERSITÀ CAMPUS BIO-MEDICO DI ROMA

**UNIVERSITÀ CATTOLICA**  
del Sacro Cuore

**SAPIENZA**  
UNIVERSITÀ DI ROMA

**TOR VERGATA**  
UNIVERSITÀ DEGLI STUDI DI ROMA

**ROMA VASCULAR FORUM**

**MAY 22-24, 2025**  
Fondazione Policlinico Gemelli Center

**SAVE THE DATE**

Registrazione organizzata presso: G.C. 151  
Modello Conferenza d'Organizzatori: 24/01/2025 Roma - Tel: +39 06 851211888 - Email: gvg@uniroma2.it