








Indications and Outcomes of the IMPEDE Embolization Plug (from Shape Memory) for Treatment of Peripheral and Visceral Artery Lesions: What Makes it Unique

Robert Morgan
St. George's Hospital,
London, UK






Indications and Outcomes of the IMPEDE Embolization Plug (from Shape Memory) for Treatment of Peripheral and Visceral Artery Lesions: What Makes it Unique

Robert Morgan
St. George's Hospital,
London, UK

Disclosures

Speaker for Medtronic, Cook, Penumbra, BD Bard, Philips, Shockwave, Shape Memory Medical

Post Market Registry CE-Marked Embolization Plugs

**IMPEDE
IMPEDE-FX
IMPEDE-FX RapidFill**
for PV Embolization

Up to 125 patients
On-label, 90d, 1y follow-up



Sponsor: Shape Memory Medical, San Jose, California, USA
Registered at clinicaltrials.gov/NCT04044443

EMBO-PMS UK

- St. George's University Hospitals NHS London
- Guy's and St Thomas' NHS London
- Imperial College-London-St. Mary's Campus
- Queen Elizabeth Hospital Birmingham


EMBO-PMS Germany

- Klinikum Stuttgart
- University Hospital UKSH Kiel
- Universität Leipzig
- University Hospital Dresden
- Uniklinikum Würzburg
- Universität Heidelberg
- Klinikum Nürnberg
- Klinikum München rechts der Isar

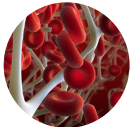



Shape Memory Polymer


Porous, polyurethane foam



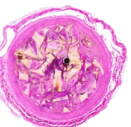
Open scaffold enables stasis and clot formation



Soft and conformable
Min radial force







Cellular growth
Tissue infiltration¹



Embolized volume converts to durable, contractile collagen

¹ACS Biomater Sci Eng 2020;6:2588-2599. Pre-clinical data on file

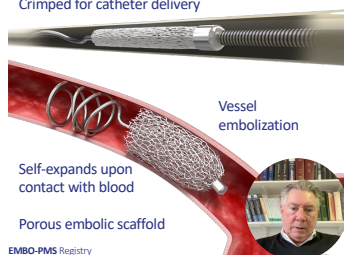





Shape Memory Polymer

Shape memory polymer is a porous polymeric material (polyurethane) that transitions between two 'memorised' shapes in different environments (temperature and aqueous)

Secondary crimped shape
For catheter delivery

Primary expanded shape
For vessel embolization






Crimped for catheter delivery

Vessel embolization

Self-expands upon contact with blood

Porous embolic scaffold

Shape Memory Polymer Product Portfolio

**IMPEDE®
Embolization Plug**

Anchor coil
Shape memory polymer
Radiopaque marker

**IMPEDE-FX
Embolization Plug**

Shape memory polymer
Radiopaque marker

Expanded Plug Diameter	Vessel Diameter
6mm	2-5mm
8mm	4-7mm
12mm	6-10mm

EMBO-PMS Registry

Radiolucent, Minimal Artifact

IMPEDE, IMPEDE-FX – Minimal Artifact

Metal Coils – CT Artifact

Park J and Park M. Endovascular Today, October 2017. Retrieved from <https://www.endovascular.com/abstracts/abstracts-of-ongoing-the-endovascular-technological-plug-symposium>

EMBO-PMS Registry

Vascular

Shape memory polymer technology in peripheral vascular embolization

Authors: Hübner T, Andros A and Brackner T Busby

10 Patients

Clinical Article

Clinical experience with a shape memory polymer peripheral vascular embolisation plug: a case series

Authors: Hübner T, Andros A and Brackner T Busby

8 Patients

EMBO-PMS Registry

EMBO-PMS UK/Germany: Vessels Treated

Vessel Treated	N
Patients Treated (PP)	82*
Vessel Treated	92
Segmental Artery	16
Ovarian Vein	15
Iliac Artery	15
Inferior Mesenteric Artery	12
Accessory Renal Artery	5
Gluteal, Inferior	5
Subclavian Artery	4
Testicular Vein	4
Renal Artery	2
Obturator Artery	2
Splenic Artery	1
Renal Artery	9
Other	1

*EDC database effective 13/08/2024

EMBO-PMS Registry

Latest Follow-Up

Variable	N
Enrolled (treated + technical failures)	82
Vessels treated	92
Series adverse events (SAEs)	7/82 (8.5%)
Device-related SAEs	0 (0.0%)
90-day follow-up visit (patients)	52
90-day sustained occlusion (patients)	44 (84.6%)
90-day follow-up visit (vessels)	58
90-day sustained occlusion (vessels)	50 (86.2%)

EMBO-PMS Registry

Right Common Iliac Artery Iliac Aneurysm

78-year-old male. Concurrent EVAR. Femoral access.

IMP-10 in 8 mm diameter right internal iliac artery

Proximal marker
Shape memory polymer
Anchor coil

EMBO-PMS Registry

Type II Endoleak after TEVAR

79-year-old male. Brachial access.
IMP-10 in 10 mm diameter left subclavian artery

6 weeks

St George's University of London
EMBO-PMS Registry
VEITH

Pelvic Venous Disease

42-year-old female. Femoral access.
2 x IMP-10 and 2 x IMP-FX-12 in x 9.3 mm dia left ovarian vein

90d vessel occlusion

St George's University of London
EMBO-PMS Registry
VEITH

Summary and Conclusions

- Small series illustrates safety and efficacy of novel shape memory polymer embolic devices for embolization of peripheral vasculature
 - Technical feasibility
 - Target vessel thrombosis
 - No device-related adverse events
- Broad utility across multiple applications for stand-alone use and in combination with other embolic devices are included
- Further experience and longer-term will demonstrate utility and of the devices

St George's University of London
EMBO-PMS Registry
VEITH

Thank you

ST GEORGE'S HOSPITAL

St George's University of London
EMBO-PMS Registry
VEITH