


Present Status of Endo Arch Repair: What Can be Done, What Can't be Done, What Changed in the Last Decade

Gustavo S. Oderich, MD, FACS
 John P. & Kathrine G. McGovern Distinguished Chair,
 Professor of Surgery, Chief of Vascular and Endovascular Surgery,
 Director of the Aortic Center


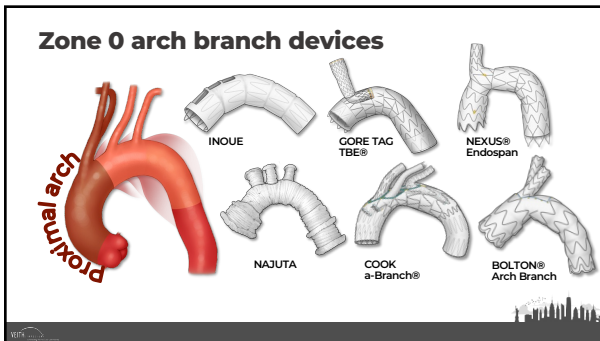
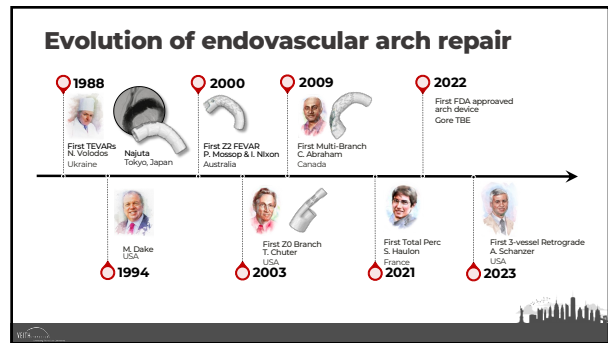
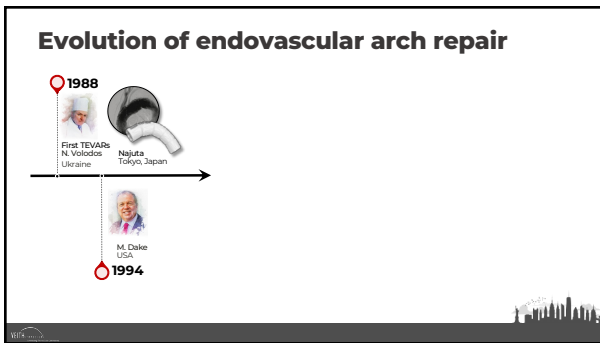
Department of Cardiothoracic & Vascular Surgery | UTHHealth Houston | McGovern Medical School | VEITH INSTITUTE | VEITH INSTITUTE | VEITH INSTITUTE



Faculty disclosures

G.S. Oderich

- **Consulting, research grants, scientific advisory board**
 WL Gore, Cook Medical Inc., GE Healthcare and Centerline Biomedical
- **Investigational use of devices**
 Cook Fenestrated and Branched Grafts
- **Special thank you**
 Research fellows: Lucas R. Kanamori MD, Bruno Schmid MD and Dora Babocs MD
 Research faculty: Ying Huang MD PhD
 Medical illustrations and graphics: David Factor and Chris Akers
 3D CTA Lab: Laura Ocasio MD and Thanila A. Macedo MD





Editor's Choice – Current Options and Recommendations for the Treatment of Thoracic Aortic Pathologies Involving the Aortic Arch: An Expert Consensus Document of the European Association for Cardio-Thoracic Surgery (EACTS) & the European Society for Vascular Surgery (ESVS)

Recommendation	Class	Level
1. Decision-making for the treatment of aortic arch pathologies by an multidisciplinary aortic team is recommended	I	C
3. Treatment of elective arch pathology is recommended to be performed in specialized centers providing open and endovascular cardiac and vascular surgery on site	I	C
3I. It is recommended that endovascular aortic arch repair is performed in centers with adequate volume of and expertise in open and endovascular arch repair	I	C

Stroke mechanisms

SOLID EMBOLIZATION	AIR EMBOLIZATION	DECREASED PERFUSION
High atheromatous burden <ul style="list-style-type: none"> - Female - Advanced age - Cerebrovascular disease - Chronic kidney disease - Ischemic cardiomyopathy - Degenerative aneurysm 	Air embolization <ul style="list-style-type: none"> - Inadequate flushing - Polyester based > Gore 	<ul style="list-style-type: none"> - Compressed lumen - Left subclavian coverage - Incomplete circle of Willis - Retrograde access - Anemia - Intraoperative hypotension - Stent kink/collapse
Imaging evidence of atheroma <ul style="list-style-type: none"> - Zone 0 > 1 > 2 		
Procedure complexity <ul style="list-style-type: none"> - Zone 0 > 1 > 2 - Tortuosity, angulation 		



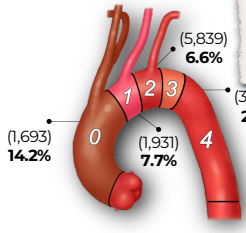
Cao et al. JACC 2021

Effect of landing zone location on stroke risk

From the Eastern Vascular Society

A meta-analysis on the effect of proximal landing zone location on stroke and mortality in thoracic endovascular aortic repair

Yanji Ma, BS,* Michael S. Siddiqui, MBBCh, David A. Farber, MD,* Francisco C. Albuquerque, MD,* Robert A. Lerman, MD,* Mark W. Long, MD,* Chuan Chen, MD,* and Daniel W. Newton, MD,* *International Vascular Practice*



Zone	Number of Patients	Stroke Risk (%)
0	1,693	14.2%
1	1,931	7.7%
2	5,839	6.6%
3	3,089	2.7%
4	-	-


- 57 studies/ **22,244** patients treated by TEVAR
- 30-day mortality: **2.9-3.7%** Zones 1-3
- **9.3%** Zone 0

Ma et al. J Vasc Surg 2023

Multicenter global early feasibility study to evaluate total endovascular arch repair using three-vessel branch stent-grafts for aneurysm and dissections

Emanuel R. Tenorio, Gustavo S. Oderich, Tilo Kölbel, Nuno V. Dias, Mark A. Farber, Carlos H. Timaran, Nikolaos Tsilimparis, Thomasz Jakimowicz and Stéphan Haulon

- 39 patients
- Mortality, 5%
- Any stroke/TIA, 5%
- **Five cervical access complications**



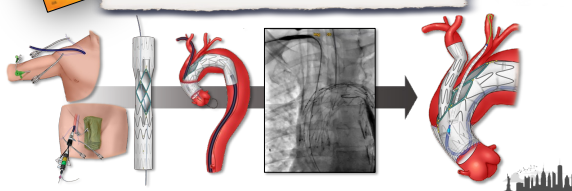
Tenorio et al. Journal of Vascular Surgery 2020

svsonline

"First in Man" Total Percutaneous Aortic Arch Repair With 3-Inner-branch Endografts

A Report of Two Cases

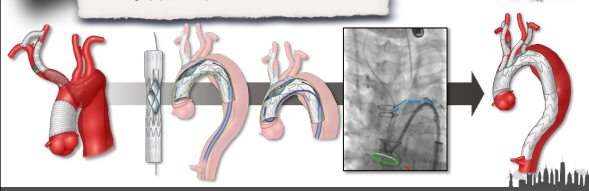
Justin Murphy, MD,* Ben Ackerly, MD,* Julian Galante, MD, PhD,* Mark E. Trivitt, PhD, MBBCh, FRCS,* Gustavo S. Oderich, MD,* Dominique Fabre, MD, PhD,* and Stephen Haulon, MD, PhD,* *Annals of Surgery*



Murphy et al. Annals of Surgery 2023

Total Transfemoral Percutaneous Endovascular Aortic Arch Repair Using 3-Vessel Inner Branch Stent-Graft

Emmanuel R. Tenorio, MD, PhD,* Roshika A. Mendis, MD,* Lissa Franklin, MD,* Marco Neri Sironi, MD, PhD,* Guillermo R. Barrios Linares, MD,* Adria Ruffino-Castellano, MD,* Anthony L. Kotnick, MD,* William Shubin, MD,* Shoaq Fahd, MD, PhD,* and Carlos H. Timaran, MD,* *JACC*

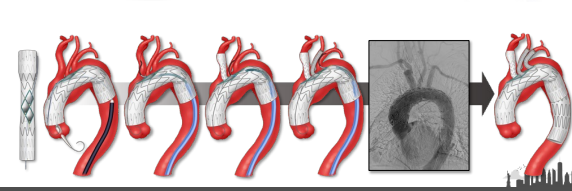


Tenorio et al. JACC 2022

Presented at Paris Vascular Insights

First-in-man all retrograde percutaneous 3-vessel arch repair (April, 2023)

Andres Schanzer MD and colleagues
Worcester MA




Schanzer et al. University of Massachusetts Lowell

What can't be done?

Contra-indication ⚠️

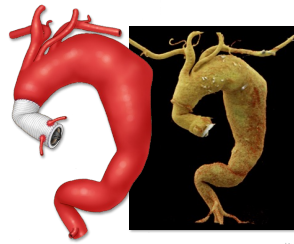
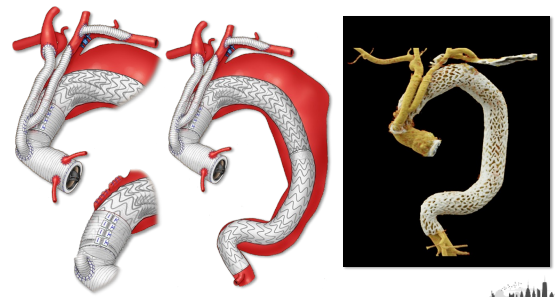
- Moderate to severe atheromatous debris affecting Zones 0-3 ("Shaggy aorta")



What can't be done?

Contra-indication ⚠️

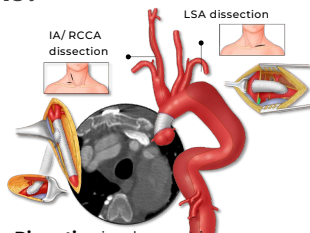
- Moderate to severe atheromatous debris affecting Zones 0-3 ("Shaggy aorta")
- Insufficient seal in zone 0 due to large diameter, kinked or too short graft

What can't be done?

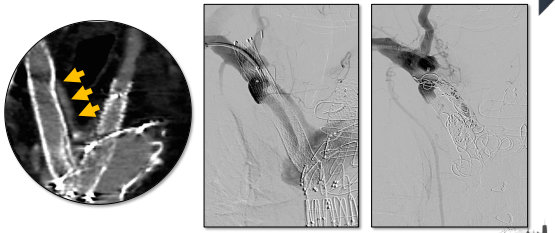
Contra-indication ⚠️

- Moderate to severe atheromatous debris affecting Zones 0-3 ("Shaggy aorta")
- Insufficient seal in zone 0 due to large diameter, kinked or too short graft
- Involvement of supra-aortic trunks



- Dissection involvement in **65%** of supra-aortic trunks:

False lumen embolization



What has changed in the last decade?

Initial experience	Current era
Cervical open surgical exposure	Total percutaneous approach
Saline flush	CO2-saline flush
Antegrade configuration	Antegrade and retrograde
Self-expandable stents	Self- and balloon-expandable stents
Focus on true lumen	Focus on true/ false lumen
	- False lumen occluder
	- Transcatheter septotomy
No options for unsuitable Zone 0	Aortic wrapping?
	Endo Bentall?

Thank You!



Department of
**Cardiothoracic &
Vascular Surgery**

UTHealth Houston
Heart & Vascular

MDAnderson
Cancer Center

UTH_CVSurgery
#UTHCVSurgery
<https://med.uth.edu/cvs/>



[@utahcvsurgery](https://med.uth.edu/cvs/)
gokorta@gmail.com