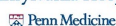

Symptoms and Current Treatment of Nutcracker Syndrome

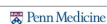Keith D. Calligaro, MD,
Kryssy Maloni, MD, Matt Carpiello, MD,
Douglas Troutman, DO, Matthew Dougherty, MD

Pennsylvania Hospital
Philadelphia, PA

51st Annual VEITH Symposium. November 19, 2024.
Pennsylvania Hospital



No Disclosure



2

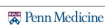CLARIFICATION

SMA Syndrome

- Compression of *duodenum* between SMA and aorta
 - Symptoms = N/V, decreased appetite
 - Rx = gastro-jejunal bypass
- DON'T WASTE TIME - REFER TO GENERAL SURGERY

Nutcracker Syndrome

- Compression of *L renal vein* between SMA and aorta (or compression of L renal vein posterior to aorta)
 - Symptoms = hematuria, L flank pain, pelvic congestion syndrome
 - Rx = L renal vein stent or L renal vein bypass
- THIS IS A VASCULAR CONDITION



3

Nutcracker Syndrome

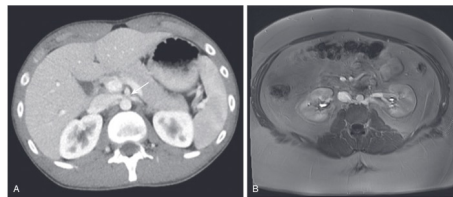
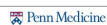

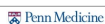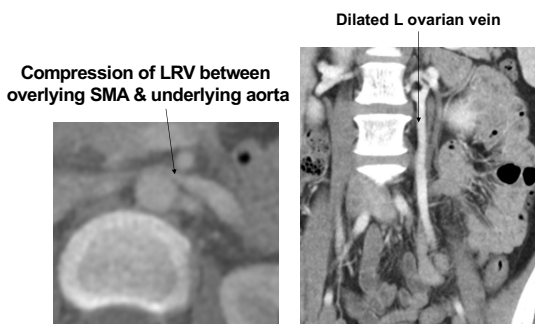
Figure 165.1 Cross-sectional imaging demonstrating (A) anterior nutcracker syndrome with compression of the left renal vein between the aorta and superior mesenteric artery as observed by computed tomography, and (B) posterior nutcracker syndrome with a retroaortic renal vein as observed by magnetic resonance imaging.

- Compression of L Renal vein between Aorta/SMA ("Anterior") or between Aorta/Spine ("Posterior")
- Symptoms - L flank pain, hematuria, pelvic pain & varicosities
- Imaging - Duplex; CT/MRI; Left renal venogram



4

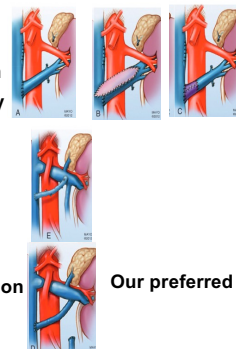
48F w/ flank and pelvis pain, +UA for blood



5

Nutcracker Syndrome – Treatment Options

- L renal vein stent (stent migration = 7%)
 - L renal vein transposition + GSV patch angioplasty + GSV cuff
 - LRV – IVC GSV bypass
 - L ovarian vein transposition
- Our preferred Rx



6

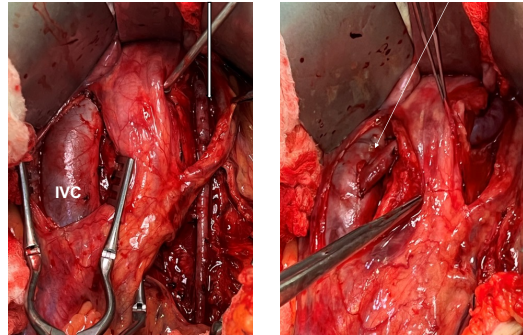
Left ovarian vein transposition

- Midline laparotomy
- Colon / small bowel retracted
- L ovarian vein dissected from L renal vein down to pelvic brim.
- Side branches tied, divide lower L ovarian V.
- Distal IVC dissected free.
- Ovarian vein tunneled under mesentery (anterior to aorta) to IVC.
- Side-biting clamp on distal IVC.
- End-to-side anastomosis.

Penn Medicine

7

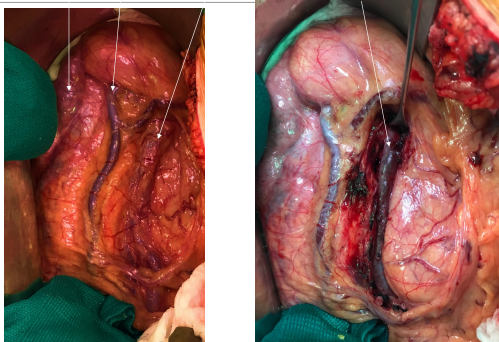
L ovarian vein transposition onto IVC



Penn Medicine

8

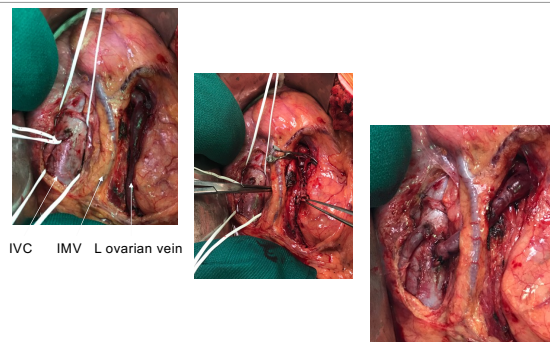
IVC IMV L ovarian vein



Penn Medicine

9

L OVARIAN VEIN TRANSPOSITION



Penn Medicine

10

CLARIFICATION

SMA Syndrome

- Compression of *duodenum* between SMA and aorta
 - Symptoms = N/V, decreased appetite
 - Rx = gastro-jejunal bypass
- DON'T WASTE TIME - REFER TO GENERAL SURGERY

Nutracker Syndrome

- Compression of *L renal vein* between SMA and aorta (or compression of L renal vein posterior to aorta)
 - Symptoms = hematuria, L flank pain, pelvic congestion syndrome
 - Rx = L renal vein stent or L renal vein bypass
- THIS IS A VASCULAR CONDITION

Penn Medicine

11



Penn Medicine

12