


Non-Aspiration Based Mechanical Thrombo-Embolectomy With The Pounce Or Rotarex : How the work and lead to more concrete procedural endpoints

Thrombectomy Devices That Truly Take Out Organized Thrombus



Gary M Ansel MD
Past System Chief for Vascular Services
OhioHealth

Healthcare Inroads
Boston, MA

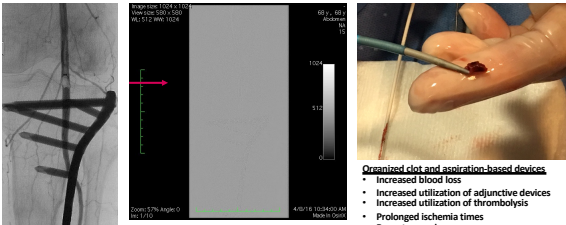
1

Disclosures

- Developed Pounce Device
- Royalties
 - Surmodics
 - Cook Medical
- SAB
 - Medtronic
 - BSC
 - Surmodics
 - Reflow Medical
 - Cardinalign
- Consulting
 - Otsuka/Venyan Medical
 - Cook Medical
 - Reflow Medical
 - Alura

2

Organized thrombus and emboli: The Achilles heal of aspiration based thrombectomy



Organized clot and aspiration-based devices

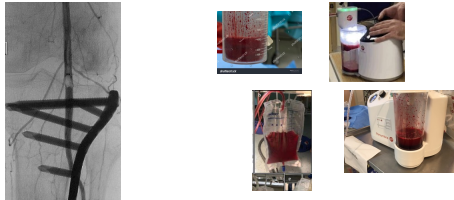
- Increased blood loss
- Increased utilization of adjunctive devices
- Increased utilization of thrombolysis
- Prolonged ischemia times
- Repeat procedures
- Increased cost
- Increased ICU usage

3

The Therapeutic Dilemma With Aspiration Based Thrombectomy


When is the procedure finished Does Not Have a Hard Endpoint?

Total Clot Removal vs. Risk of significant blood loss



4

Rotarex Mechanism of Action (Combination Aspiration and Mechanical "AtheroThrombectomy")

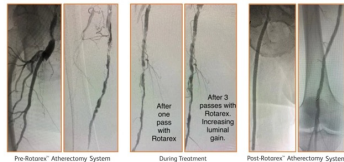


Currently limited to vessels 3mm or larger

- Catheter head and helix**
 - Rotation
 - 40,000 rpm with the 8F catheter
 - 60,000 rpm with the 6F catheter
- Rotating abrading vortex**
 - Vortex creates additional luminal gain around the cylinder
 - Large side windows further break down and efficiently remove detached material
- Continuous active aspiration**
 - Internal helix creates negative pressure at the tip to actively aspirate and transport material away

5

Rotarex Case Example



Pre-Rotarex[®] Atherectomy System During Treatment Post-Rotarex[®] Atherectomy System

Dr John Park, Omaha Nebraska

6

Rotarex Multi-Center Trial

Overview

- Multicenter, prospective trial
- 220 pts, 24 mo results
- Acute, subacute, chronic thrombus
 - Acute = 14.1%
 - Subacute = 59.2%
 - Chronic = 27.7%
- Lesion length mean = 20.9 cm
- Lesion type
 - Native artery = 39.5%
 - Stent/Graft = 53.6%
 - Bypass/AV fistula = 6.8%
- Results
 - Tech success
 - 47.2% stand alone
 - 94.1% with adjunctive devices
 - 88.5% stenosis reduction (procedural)

Michael Lichtenberg: LINC and VIVA 23

Chronic limb ischemia (n = 206)	n	%
0 = Asymptomatic	0	0
1 = Mild claudication	0	0
2 = Moderate claudication	13	6.5
3 = Severe claudication	306	53.0
4 = Ischemic rest pain	52	26.0
5 = Minor tissue loss, non-healing ulcers	29	14.5
6 = Major tissue loss, extending above trans-tarsal level	0	0

Primary Patency	
1 Month	87.2% (130/149)
6 Months	68.1% (111/163)
12 Months	57.8% (101/174)
24 Months	49.1% (83/169)

7

Pounce™ Fully Mechanical Thrombectomy System (Think Percutaneous Fogarty®)

The diagram illustrates the Pounce system components and their application. Key features include:

- Integrated handle with slider button** for sheathing and unsheathing funnel. Wire lock maintains basket wire position in funnel during thrombus or embolus removal.
- 7 mm diameter, 6.5 cm long funnel** to capture baskets and restrain clot.
- Integrated radiopaque wires** for enhanced visibility.
- Inner and outer layered nitinol mesh funnel**.
- Dual 6 mm (vessel 3.5-6mm) or 4mm (vessel 2-4mm) diameter nitinol self-expanding baskets** mounted to series on a .026 diameter core wire for capturing thrombus.
- Integrated radiopaque markers** on basket struts for visibility during deployment and capture of clot.
- Basket wire's tapered tip** includes a safety coil for atraumatic delivery.

Three basket sizes are shown: 3-4mm vessel diameter, 3.5-6mm vessel diameter, and 4-5mm vessel diameter.

8

How it Works?

The Pounce™ Thrombectomy System is comprised of three components: a delivery catheter, a basket wire, and a funnel catheter.

The basket wire is delivered distal to the location of the thrombus, deploying two nitinol self-expanding baskets.

The baskets capture the clot and are retracted into a nitinol collection funnel.

With the clot entrained, the system is retracted into a minimum 7 Fr guide sheath through which the clot is withdrawn and removed from the body.

9

Case Example: Chronic Symptoms

- 5-mo hx of Rt leg rest pain
- ABI = .31

The case example shows a patient with chronic symptoms. The angiogram displays a significant stenosis in the right femoral artery. Clinical photos show the patient's leg and the procedure site.

10

Case : Final Angio without PTA or Stents

The final angiogram shows a clear, unobstructed vessel lumen, indicating successful thrombectomy without the need for PTA or stents.

6 extractions from proximal tibial to proximal SFA

Compliments Dr Bruce Gray

11

Case: Emboli to Left Brachial Artery

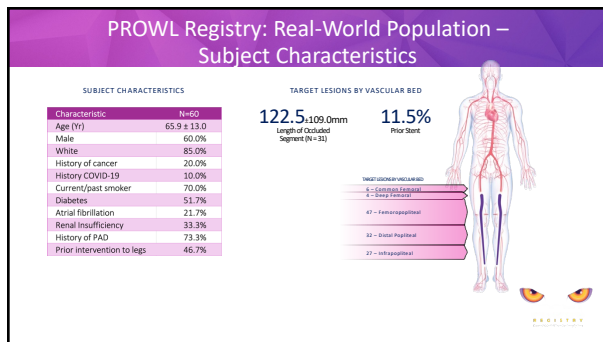
- Elderly female with acute on chronic left arm ischemia
- Very ectatic/aneurysmal subclavian artery

PRE

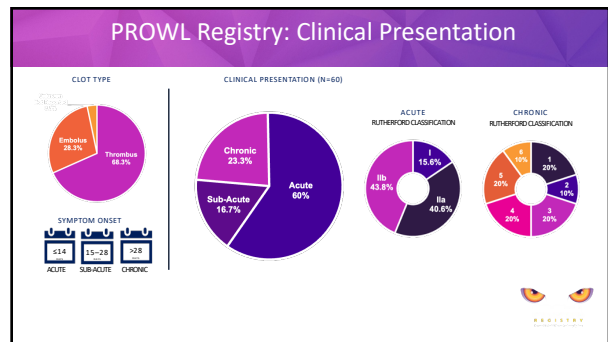
Post

Compliments M Bacharach


12



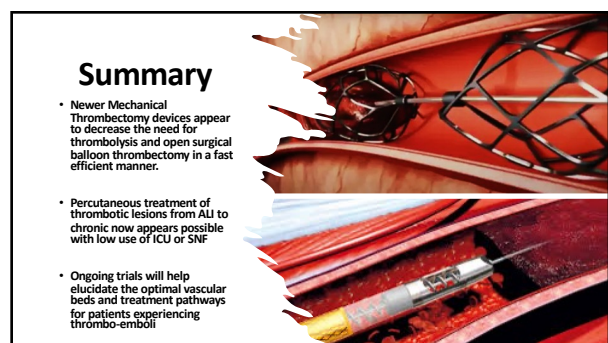
13



14



15



16