

Clinic for Vascular Surgery and Phlebology
Institute for Vascular Research
Director: PD Dr. M. J. Austermann

FRANZISKUS STIFTUNG

St. Franziskus Hospital Münster
Hohenzollernring 70
48145 Münster

Single Branched TEVAR In A Complex Thoracoabdominal Dissection

M. J. Austermann
Director
Clinic for Vascular Surgery and Phlebology
St. Franziskus Hospital Münster
Germany

Clinic for Vascular Surgery and Phlebology
Institute for Vascular Research
Director: PD Dr. M. J. Austermann

FRANZISKUS STIFTUNG

St. Franziskus Hospital Münster
Hohenzollernring 70
48145 Münster

Disclosure **PD Dr. med. Martin J. Austermann**
Director Clinic for Vascular Surgery
St. Franziskus Hospital Münster

Speaker name:

I have the following potential conflicts of interest to report:

- Receipt of grants/research support
- Receipt of honoraria and travel support
- Participation in a company-sponsored speaker bureau
- Employment in industry
- Shareholder in a healthcare company
- Owner of a healthcare company

I do not have any potential conflict of interest

Clinic for Vascular Surgery and Phlebology
Institute for Vascular Research
Director: PD Dr. M. J. Austermann

FRANZISKUS STIFTUNG

St. Franziskus Hospital Münster
Hohenzollernring 70
48145 Münster

Single Branched TEVAR In A Complex Thoracoabdominal Dissection

Male 69 Y

EVAR in 1/2018. Six month later Type B Dissection above the endograft. Conservativ therapy. Now growing AAA due to a type 1 endoleak and neck degeneration. Growing thoracoabdominal dissection.

History:
Arterial hypertension

Clinical examination:
Aneurysm pulsating palpable without pain. Peripheral pulses palpable.

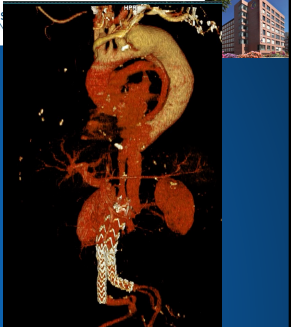
Clinic for Vascular Surgery and Phlebology
Institute for Vascular Research
Director: PD Dr. M. J. Austermann

FRANZISKUS STIFTUNG

St. Franziskus Hospital Münster
Hohenzollernring 70
48145 Münster

Single Branched TEVAR in a complex thoracoabdominal dissection

Male 69 Y



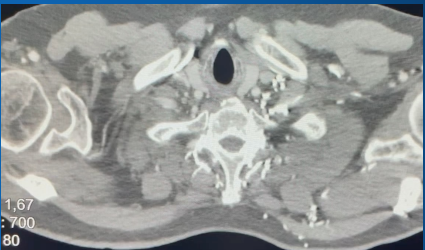
Clinic for Vascular Surgery and Phlebology
Institute for Vascular Research
Director: PD Dr. M. J. Austermann

FRANZISKUS STIFTUNG

St. Franziskus Hospital Münster
Hohenzollernring 70
48145 Münster

Single Branched TEVAR In A Complex Thoracoabdominal Dissection

Male 69 Y




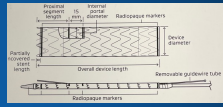
1,67
700
80

Clinic for Vascular Surgery and Phlebology
Institute for Vascular Research
Director: PD Dr. M. J. Austermann

FRANZISKUS STIFTUNG

St. Franziskus Hospital Münster
Hohenzollernring 70
48145 Münster

Single Branched TEVAR In A Complex Thoracoabdominal Dissection

Device	Length	Stent length	Branch length	Branch diameter	Branch angle	Branch diameter	Branch angle	Branch diameter	Branch angle
1	200	100	100	28	90	28	90	28	90
2	200	100	100	28	90	28	90	28	90
3	200	100	100	28	90	28	90	28	90
4	200	100	100	28	90	28	90	28	90
5	200	100	100	28	90	28	90	28	90
6	200	100	100	28	90	28	90	28	90
7	200	100	100	28	90	28	90	28	90
8	200	100	100	28	90	28	90	28	90
9	200	100	100	28	90	28	90	28	90
10	200	100	100	28	90	28	90	28	90
11	200	100	100	28	90	28	90	28	90
12	200	100	100	28	90	28	90	28	90
13	200	100	100	28	90	28	90	28	90
14	200	100	100	28	90	28	90	28	90
15	200	100	100	28	90	28	90	28	90
16	200	100	100	28	90	28	90	28	90
17	200	100	100	28	90	28	90	28	90
18	200	100	100	28	90	28	90	28	90
19	200	100	100	28	90	28	90	28	90
20	200	100	100	28	90	28	90	28	90
21	200	100	100	28	90	28	90	28	90
22	200	100	100	28	90	28	90	28	90
23	200	100	100	28	90	28	90	28	90
24	200	100	100	28	90	28	90	28	90
25	200	100	100	28	90	28	90	28	90
26	200	100	100	28	90	28	90	28	90
27	200	100	100	28	90	28	90	28	90
28	200	100	100	28	90	28	90	28	90
29	200	100	100	28	90	28	90	28	90
30	200	100	100	28	90	28	90	28	90
31	200	100	100	28	90	28	90	28	90
32	200	100	100	28	90	28	90	28	90
33	200	100	100	28	90	28	90	28	90
34	200	100	100	28	90	28	90	28	90
35	200	100	100	28	90	28	90	28	90
36	200	100	100	28	90	28	90	28	90
37	200	100	100	28	90	28	90	28	90
38	200	100	100	28	90	28	90	28	90
39	200	100	100	28	90	28	90	28	90
40	200	100	100	28	90	28	90	28	90
41	200	100	100	28	90	28	90	28	90
42	200	100	100	28	90	28	90	28	90
43	200	100	100	28	90	28	90	28	90
44	200	100	100	28	90	28	90	28	90
45	200	100	100	28	90	28	90	28	90
46	200	100	100	28	90	28	90	28	90
47	200	100	100	28	90	28	90	28	90
48	200	100	100	28	90	28	90	28	90
49	200	100	100	28	90	28	90	28	90
50	200	100	100	28	90	28	90	28	90

